

Bandar Al-Ghamdi*, Azam Shafquat and Yaseen Mallawi

Heart Centre, King Faisal Specialist Hospital and Research Centre (KFSH&RC), College of Medicine, Alfaisal University, Riyadh, Saudi Arabia

Dates: Received: 14 May, 2016; Accepted: 24 May, 2016; Published: 25 May, 2016

*Corresponding author: Bandar Al-Ghamdi, MD, Heart Centre, King Faisal Specialist Hospital and Research Centre, MBC-16, PO Box 3354, Riyadh, 11211 Saudi Arabia, Tel: +966-011-464-7272; Ext: 31584; Fax: +966-011-442-7791; E-mail: balghamdi@kfsrhc.edu.sa

www.peertechz.com

ISSN: 2455-2976

Keywords: S-ICD; CCM; Heart failure; Sudden death

Review Article

Cardiac Contractility Modulation Device and Subcutaneous Implantable Cardioverter Defibrillator Combination: A New Hope for Heart Failure Patients with Low Ejection Fraction and Narrow QRS Complex

Abstract

Background: Heart failure (HF) is a common cardiovascular disease with high rates of morbidity and mortality despite advances in medical and device-related management. Cardiac Contractility Modulation (CCM) is a promising therapy in HF patients with narrow QRS complex and CCM devices are approved and available for clinical use in Europe. On the other hand, there has recently been an increased interest in subcutaneous implantable cardioverter defibrillators (S-ICD) in HF patients with low ejection fraction. S-ICDs obviate the vascular and lead complications associated with conventional ICDs. There are limited data about the combination of CCM and S-ICD in management of HF patients.

Methods: We reviewed literature about current use of CCM and S-ICD as well as data on their use in combination. We are also reporting our first case with this combination.

Results: The combination of the two devices is feasible, seems to be safe, and is without significant interaction between the two systems.

Conclusion: CCM and S-ICD combination in patients with HF, functional class II-IV, low ejection fraction, and narrow QRS is an attractive approach as it avoids numerous leads inside the body. However, more studies are needed to prove that this approach is effective and has good clinical outcome.

Introduction

Heart failure is a common cardiovascular disease with a high morbidity and mortality despite advances in medical and device-related management. Cardiac resynchronization therapy (CRT) which is also known as biventricular pacing has proven to be an effective treatment in heart failure [1-6]. However, CRT is generally recommended for patients in sinus rhythm and prolonged QRS complex (≥ 120 ms) with left bundle branch block (LBBB), or a QRS complex width of ≥ 150 ms in the absence of LBBB [6]. On the other hand, only 30-40% of all heart failure patients show such a prolonged QRS complex [7,8] and therefore the 60-70% of patients who have a normal QRS complex cannot be treated with CRT. Furthermore, around 30% of the patients eligible for CRT treatment do not respond to CRT [7,8].

Heart failure patients with low ejection fraction and narrow QRS complexes benefit from Cardiac Contractility Modulation (CCM) however they are also at risk for sudden cardiac death (SCD) [8]. Guidelines for prevention of sudden cardiac death are well

described and include the use of implantable cardiac defibrillators (ICDs). In heart failure patients who do not require pacing or CRT but are candidates for CCM, the use of subcutaneous implantable cardioverter defibrillator devices (S-ICD) is a proven and attractive option especially compared to transvenous ICD systems. CCM paired with S-ICD provides the preferred treatment options while minimizing intravascular leads [9].

The aim of this review is to have an overview of these two technologies and its combination, and to give an example of a successful combination.

Cardiac contractility modulation (CCM)

CCM is a cardiac implantable electronic device (CIED) that enhances ventricular contractile strength of the failing myocardium, with delivering a high voltage non-excitatory electrical impulses during the absolute refractory period state of the cardiac muscle cells independently of synchrony of myocardial contraction [10-13]. These signals do not initiate a new contraction or affect activation sequence [14].

The CCM signals are relatively high-voltage electrical impulses delivered to the myocardium 30–40 ms after detection of local myocardial activation during the absolute refractory period (Figure 1). A bi-phasic square wave pulse is the most common waveform utilized. The CCM pulses can be described by parameters of phase duration, delay from activation and signal amplitude. Studies of the mechanisms underlying the acute and prolonged effects of CCM signals have focused on their impact on action potentials, peak intracellular calcium, calcium loading of the sarcoplasmic reticulum and gene expression [10,15,16].

The CCM signals cause an increase in myocyte calcium in the cytosol during systole. This increases the muscle contraction strength. Additionally, within minutes, cell metabolism and gene expression, which are typically abnormal in heart failure, improve towards their normal state [17]. This beneficial effect occurs initially only in the area adjacent to the electrodes, but with time also spreads to remote areas of the cardiac muscle [17]. CCM, therefore restores the structure and function of damaged cells back towards their normal state. In some cases, disease-related changes in the ventricular heart structure can be partially reversed by CCM through a process known as reverse remodeling of the heart [18–22]. To date, the only clinically available system for CCM delivery is the OPTIMIZER™IVs system (Impulse Dynamics Inc., Orangeburg, NJ, USA). The device is similar to pacemaker and consists of four components, Implantable Pulse Generator (IPG), leads (one atrial and two ventricular leads), Battery charger, and programming unit (Figure 2). It is implanted into the pectoral region in a minimally invasive procedure and three bipolar pacemaker leads are introduced into the right side of the heart via the subclavian vein (commonly TENDRIL ST, SJM, St. Paul, MN, USA). One lead is placed into the right atrium to detect the atrial electrical



Figure 2 : a) Optimizer IVs Active Implantable Pulse Generator. b) Device programmer. c) External charger used to recharge the battery of the generator on a weekly basis.

activity. Two leads are positioned about 2 cm apart at the ventricular septum for delivery of impulses [7,23].

Based on the approval of CCM devices, cardiac contractility modulation is a treatment option for patients who are at least 18 years old who suffer from heart failure symptoms due to left ventricular systolic dysfunction (LVSD) despite adequate medical treatment. Further clinical research is required to identify which patient group within the scope of the device approval benefits most from CCM treatment [18, 24].

Most clinical studies on CCM therapy have involved heart failure patients who were classified initially as NYHA Class II, III or IV and had a normal QRS duration (QRS duration ≤ 120 ms). The efficacy of CCM on patients in an earlier stage of heart failure has not yet been studied [7, 24]. A subsequent evaluation study (subgroup analysis) has already suggested a particular patient group that responds exceptionally well to CCM therapy. The patients were characterized by a disease severity of NYHA class III and a left ventricular ejection fraction of $\geq 25\%$ [25,26]. Cardiac contractility modulation has proven to be effective and safe in randomized controlled trials involving several hundred patients [27–30]. Meta-analyses studying the efficacy of CCM therapy on heart failure [24,31], showed that CCM significantly improved important markers of cardiac performance including the maximal oxygen uptake (peak VO₂ or pVO₂ – measured by ventilatory parameters during a cardiopulmonary exercise test), which is indicative of improved survival [32] and the 6-minute walk test. There was a significant improvement in quality of life of participating patients, measured by the Minnesota Living with Heart Failure Questionnaire (MLWHFQ). However, both meta-analyses demanded additional and larger randomized controlled trials in order to evaluate the effect of CCM more precisely. There are reports of lower long-term mortality rates in heart failure patients with NYHA (II–III) and QRS ≤ 130 ms when treated by CCM than predicted for the cohort. These findings warrant substantiation in a prospective study [33–35].

Currently, the CCM is only indicated in patients with sinus rhythm however experience with CCM in patients with heart failure and atrial fibrillation has been described [36].

The CCM devices are approved and available for clinical use in all European Union countries and in Australia, Turkey, India and Hong Kong, as well as in other countries that recognize CE marking for medical devices. CCM therapy is not yet approved for clinical use in the United States; however, a study has been initiated in order to

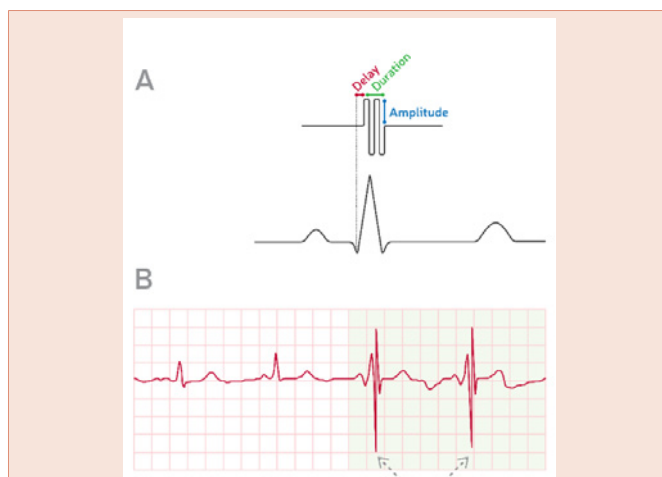


Figure 1 : A) Illustration of CCM signal delivery in relation to the cardiac cycle with the three characteristic signal parameters: amplitude, duration and delay. B) Illustration of an ECG of a heart failure patient with a CCM device. The first two beats are shown with “CCM Off” and the last two beats with “CCM On”. This illustration is based on an actual ECG recording of a patient with a CCM device (Borggreve M, Burkhoff D. Clinical effects of cardiac contractility modulation (CCM) as a treatment for chronic heart failure. *Eur J Heart Fail.* 2012 Jul; 14(7):703–12. DOI: 10.1093/eurjhf/hfs078. PMID 22696514. (Adapted with permission).

obtain FDA approval. (Clinicaltrials.gov Announcement of a study that will further investigate safety and efficacy of CCM devices).

Subcutaneous implantable cardioverter defibrillator (S-ICD)

The introduction of the implantable cardioverter-defibrillator (ICD) into clinical practice over the past 25 years has provided a life-saving therapy for primary and secondary prevention of SCD. The ICD technology evolved from devices that delivered therapy through epicardial patch electrodes introduced by thoracotomy in 1980s [34], to those using transvenous leads advanced to the right ventricle for detection and treatment of tachyarrhythmia and to provide bradycardia-pacing support in 1990s. The transvenous ICD reduced the morbidity and risk associated with thoracotomy implants. However, use of transvenous leads involves potential complications which may happen acutely such as lead dislodgement, pneumothorax, hemopericardium, cardiac perforation, pericardial effusion, and cardiac tamponade, or chronically such as device-related infection, lead malfunction, inappropriate shocks, and venous occlusion [37-41].

The need to completely avoid venous access issues, endovascular mechanical stress producing lead malfunction, and extraction-associated risks led to the development of the entirely subcutaneous ICD (S-ICD) [9]. Its unique design avoids endovascular leads, thus eliminating many of the complications associated with the traditional transvenous-ICD [9]. The S-ICD (Boston Scientific, Marlborough, Massachusetts) consists of a pulse generator and single lead with a shock coil. The pulse generator is implanted in the left axillary position, between the anterior and mid-axillary lines near the apex of the left ventricle. A single lead for sensing and defibrillation is tunneled from the lateral pocket medially to the xiphoid process and subsequently cephalad and is usually positioned 1 to 2 cm to the left of and parallel to the sternum, with the distal tip near the manubriosternal junction. Using the pulse generator as a third electrode provides 3 potential sensing vectors (pulse generator to proximal or distal electrode and distal to proximal electrode). The shock vector is from pulse generator to coil and is reversed if more than one shock is needed to terminate an arrhythmia (Figure 3) [42]. The S-ICD lacks functionality for bradycardia or antitachycardia pacing, but can provide up to 30 s of post-shock transthoracic pacing [43].

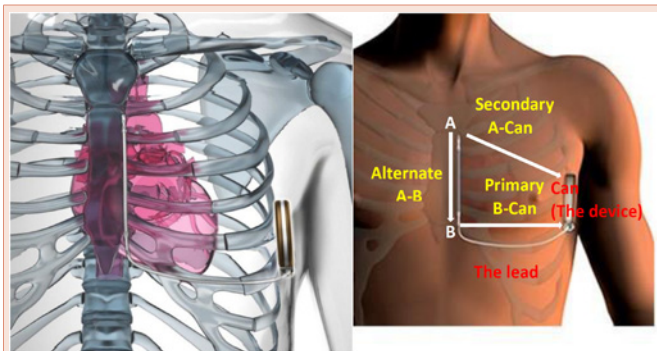


Figure 3 : Subcutaneous Implantable Cardioverter-Defibrillator device and lead with demonstration of the three sensing vectors. A = distal electrode, B= proximal electrode.

The initial feasibility, safety, and effectiveness of subcutaneous defibrillation were established in earlier human studies of the S-ICD System [44,45]. The S-ICD provides a useful alternative for high-energy (ICD) therapy in those deemed at risk and who need defibrillation and in whom there are no indications for cardiac resynchronization, bradycardia support or anti-tachycardia pacing [46].

The S-ICD has developed and tested over the past decade and demonstrated high efficacy for detection and termination of ventricular arrhythmias. Complications and inappropriate shock rates were reduced consistently with strategic programming and as operator experience increased. These data provide further evidence for the safety and efficacy of the S-ICD [43,47]. S-ICD received CE Mark approval in Europe in 2008, and U.S. Food and Drug Administration approval in 2012.

Case demonstration of the CCM and S-ICD combination

Our first patient with CCM and S-ICD combination was a 50-year old male patient with history of ischemic heart disease, as he sustained anterior wall myocardial infarction (MI), and underwent a percutaneous coronary intervention with stent to left anterior descending artery (LAD), 2 years prior to presentation. His cardiac risk factors include smoking, which he quit at the time of his MI, dyslipidemia, and a positive family history of ischemic heart disease. His left ventricular ejection fraction dropped over 16 months from 40% to < 25% despite being on optimal medical therapy. He underwent S-ICD implantation for primary prevention of sudden cardiac death with no complications. He was still complaining of shortness of breath (SOB), New York Heart Association (NYHA) functional class- III. There was no history of orthopnea or paroxysmal nocturnal dyspnea. His 12-lead CG showed a narrow QRS complex. The option of CCM was discussed with the patient and he accepted it. The device was implanted into the left pectoral region- as per patient wish, one pacemaker lead was placed at the right atrium and two pacemaker leads were placed at the right ventricular septum via the left subclavian vein. During the procedure, a cross talk test with the activated CCM device was performed using the three sensing configurations of the S-ICD. The primary vector showed noise during CCM activation but the secondary vector demonstrated accurate sensing with minimal noise and absence of double detection of ventricular signals, despite active CCM stimulation. The procedure was uneventful. The chest X-ray post procedure is shown in Figure 4. On 3 and 6 months follow-up, he was feeling better with SOB on exertion NYHA functional state I. Six minutes' walk test showed improvement in the walked distance from 363 meters to 528 meters.

On cardiopulmonary exercise testing, his maximal oxygen consumption/maximal oxygen uptake (VO₂ max) improved from 15.9 to 19.7ml/kg/min.

His echocardiogram showed improvement of LVEF from <25% to 30%.

Discussion

Successful combination of CCM and S-ICD devices has been described [23,48]. In six patients who were treated by S-ICD in

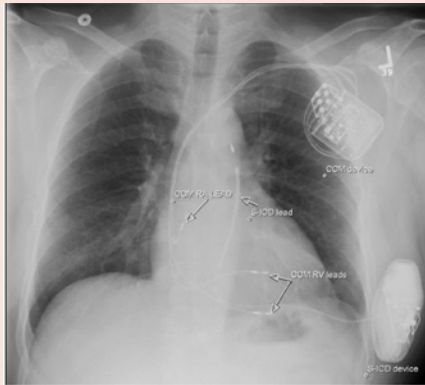


Figure 4: Posteroanterior (PA) chest X-ray view of a patient with subcutaneous ICD (S-ICD) and Cardiac Contractility Modulation (CCM) devices and leads.

combination with CCM, crosstalk testing between the two systems was performed and at least 1 of the 3 S-ICD vectors showed “noise-free” ventricular sensing during CCM activity, and this vector was selected for use. All 5 patients had successful intraoperative S-ICD testing during CCM signal delivery, and none showed signs of over sensing during exercise testing or provocation maneuvers [23]. This study showed that in suitable patients, combining an S-ICD with CCM might provide an acceptable means to reduce the number of transvascular leads. S-ICD appeared safe with CCM over an intermediate follow-up period. Additional prospective randomized controlled trials examining S-ICD in conjunction with CIEDs are warranted [23].

Conclusion

The combination of CCM and S-ICD technology is safe and provides attractive approach in patients with heart failure NYHA FC II-IV, low ejection fraction, and narrow QRS complex. This combination has the advantages of defibrillation therapy and CCM heart failure management with less intravascular hardware.

Improvement in CCM technology with using a single or dual leads would further simplify the use of this combination. A CCM device with defibrillation capability would be more ideal.

References

- Bristow MR, Saxon LA, Boehmer J, Krueger S, Kass DA, et al. (2004) Cardiac-resynchronization therapy with or without an implantable defibrillator in advanced chronic heart failure. *N Engl J Med* 350: 2140-2150.
- Cleland JG, Daubert JC, Erdmann E, Freemantle N, Gras D, et al. (2005) The effect of cardiac resynchronization on morbidity and mortality in heart failure. *N Engl J Med* 352: 1539-1549.
- Cleland JG, Daubert JC, Erdmann E, Freemantle N, Gras D, et al. (2006) Longer-term effects of cardiac resynchronization therapy on mortality in heart failure [the CArdiac REsynchronization-Heart Failure (CARE-HF) trial extension phase]. *Eur Heart J* 27: 1928-1932.
- Moss AJ, Brown MW, Cannom DS, Daubert JP, Estes M, et al. (2005) Multicenter Automatic Defibrillator Implantation Trial–Cardiac Resynchronization Therapy (MADIT-CRT): Design and Clinical Protocol. *Ann Noninvasive Electrocardiol* 10: 34-43.
- Moss AJ, Hall WJ, Cannom DS, Klein H, Brown MW, et al. (2005) Cardiac-resynchronization therapy for the prevention of heart failure events. *N Engl J Med* 361: 1329-1338.
- McMurray JJV, Adamopoulos S, Anker SD, Auricchio A, Böhm M, et al. (2012) ESC Committee for Practice Guidelines. ESC Guidelines for the diagnosis and treatment of acute and chronic heart failure 2012: The Task Force for the Diagnosis and Treatment of Acute and Chronic Heart Failure 2012 of the European Society of Cardiology. Developed in collaboration with the Heart Failure Association (HFA) of the ESC. *Eur Heart J* 33: 1787-1847.
- Kuck KH, Bordachar P, Borggrefe M, Boriani G, Burri H, et al. (2014) New devices in heart failure: an European Heart Rhythm Association report: developed by the European Heart Rhythm Association; endorsed by the Heart Failure Association. *Europace* 16: 109-128.
- Burkhoff D (2011) Does contractility modulation have a role in the treatment of heart failure? *Curr Heart Fail Rep* 8: 260-265.
- Aziz S, Leon AR, El-Chami MF (2014) The subcutaneous defibrillator: a review of the literature. *J Am Coll Cardiol* 63:1473-1479.
- Sabbah HN, Haddad W, Mika Y, Nass O, Aviv R, et al. (2001) Cardiac contractility modulation with the impulse dynamics signal: studies in dogs with chronic heart failure. *Heart Fail Rev* 6: 45-53.
- Mohri S, He KL, Dickstein M, Mika Y, Shimizu J, et al. (2002) Cardiac contractility modulation by electric currents applied during the refractory period. *Am J Physiol Heart Circ Physiol* 282: H1642-1647.
- Lawo T, Borggrefe M, Butter C, Hindricks G, Schmidinger H, et al. (2005) Electrical signals applied during the absolute refractory period: an investigational treatment for advanced heart failure in patients with normal QRS duration. *J Am Coll Cardiol* 46: 2229-2236.
- Abraham WT, Burkhoff D, Nademanee K, Carson P, Bourge R, et al. (2008) A randomized controlled trial to evaluate the safety and efficacy of cardiac contractility modulation in patients with systolic heart failure: rationale, design, and baseline patient characteristics. *Am Heart J* 156: 641-648.
- Burria H, Bordachar P (2013) Cardiac contractility modulation for treatment of heart failure. *Cardiovascular Medicine* 16: 259-262.
- Brunckhorst CB, Shemer I, Mika Y, Ben-Haim SA, Burkhoff D (2006) Cardiac contractility modulation by non-excitatory currents: studies in isolated cardiac muscle. *Eur J Heart Fail* 8: 7–15.
- Mohri S, Shimizu J, Mika Y, Shemer I, Wang J, et al. (2003) Electric currents applied during refractory period enhance contractility and systolic calcium in the ferret heart. *Am J Physiol Heart Circ Physiol* 284: H1119–1123.
- Lyon AR, Samara MA, Feldman DS (2013) Cardiac contractility modulation therapy in advanced systolic heart failure. *Nat Rev Cardio* 10: 584-598.
- Borggrefe M, Burkhoff D (2012) Clinical effects of cardiac contractility modulation (CCM) as a treatment for chronic heart failure. *Eur J Heart Fail* 14: 703-712.
- Butter C, Rastogi S, Minden HH, Meyhöfer J, Burkhoff D, et al. (2008) Cardiac contractility modulation electrical signals improve myocardial gene expression in patients with heart failure. *J Am Coll Cardiol* 51: 1784-1789.
- Yu CM, Chan JY, Zhang Q, Yip GW, Lam YY, et al. (2009) Impact of cardiac contractility modulation on left ventricular global and regional function and remodeling. *JACC Cardiovasc Imaging* 2: 1341-1349.
- Imai M, Rastogi S, Gupta RC, Mishra S, Sharov VG, et al. (2007) Therapy with cardiac contractility modulation electrical signals improves left ventricular function and remodeling in dogs with chronic heart failure. *J Am Coll Cardiol* 49: 2120-2128.
- Gupta RC, Mishra S, Wang M, Jiang A, Rastogi S, et al. (2009) Cardiac contractility modulation electrical signals normalize activity, expression, and phosphorylation of the Na⁺-Ca²⁺ exchanger in heart failure. *J Card Fail* 15: 48-56.
- Kuschyk J, Stach K, Tülümen E, Rudic B, Liebe V, et al. (2015) The Subcutaneous Implantable Cardioverter-Defibrillator – First Single Center Experience with other Cardiac Implantable Electronic Devices. *Heart Rhythm* 12: 2230-2238.
- Giallauria F, Vigorito C, Piepoli MF, Stewart Coats AJ (2014) Effects of cardiac contractility modulation by non-excitatory electrical stimulation on

- exercise capacity and quality of life: an individual patient's data meta-analysis of randomized controlled trials. *Int J Cardiol* 175: 352-357.
25. Abraham WT, Smith SA (2012) Devices in the management of advanced, chronic heart failure. *Nat Rev Cardiol* 10: 98-110.
26. Abraham WT, Nademanee K, Volosin K, Krueger S, Neelagaru S, et al. (2011) Subgroup analysis of a randomized controlled trial evaluating the safety and efficacy of cardiac contractility modulation in advanced heart failure. *J Card Fail* 17: 710-717.
27. Neelagaru SB, Sanchez JE, Lau SK, Greenberg SM, Raval NY, et al. (2006) Nonexcitatory, cardiac contractility modulation electrical impulses: feasibility study for advanced heart failure in patients with normal QRS duration. *Heart Rhythm* 3: 1140-1147.
28. Borggrefe MM, Lawo T, Butter C, Schmidinger H, Lunati M, et al. (2008) Randomized, double blind study of non-excitatory, cardiac contractility modulation electrical impulses for symptomatic heart failure. *Eur Heart J* 29: 1019-1028.
29. Kadish A, Nademanee K, Volosin K, Krueger S, Neelagaru S, et al. (2011) A randomized controlled trial evaluating the safety and efficacy of cardiac contractility modulation in advanced heart failure. *Am Heart J* 161: 329-337.
30. Abraham WT, Lindenfeld J, Reddy VY, Hasenfuss G, Kuck KH, et al. (2015) A randomized controlled trial to evaluate the safety and efficacy of cardiac contractility modulation in patients with moderately reduced left ventricular ejection fraction and a narrow QRS duration: study rationale and design. *J Card Fail* 21: 16-23.
31. Kwong JS, Sanderson JE, Yu CM (2012) Cardiac contractility modulation for heart failure: a meta-analysis of randomized controlled trials. *Pacing Clin Electrophysiol* 35: 1111-1118.
32. Pakarinen S, Oikarinen L, Toivonen L (2010) Short-term implantation-related complications of cardiac rhythm management device therapy: a retrospective single-centre 1-year survey. *Europace* 12: 103-108.
33. Kloppe A, Lawo T, Mijic D, Schiedat F, Muegge A, et al. (2016) Long-term survival with Cardiac Contractility Modulation in patients with NYHA II or III symptoms and normal QRS duration. *Int J Cardiol* 209: 291-295.
34. Liu M, Fang F, Luo XX, Shlomo BH, Burkhoff D, et al. (2016) Improvement of long-term survival by cardiac contractility modulation in heart failure patients: A case-control study. *Int J Cardiol* 206: 122-126.
35. Kuschyk J, Roeger S, Schneider R, Streitner F, Stach K, et al. (2015) Efficacy and survival in patients with cardiac contractility modulation: Long-term single center experience in 81 patients. *Int J Cardiol* 183: 76-81.
36. Röger S, Schneider R, Rudic B, Liebe V, Stach K, et al. (2014) Cardiac contractility modulation: first experience in heart failure patients with reduced ejection fraction and permanent atrial fibrillation. *Europace* 16: 1205-1209.
37. Mirowski M, Reid PR, Mower MM, Watkins L, Gott VL, et al. (1980) Termination of malignant ventricular arrhythmias with an implanted automatic defibrillator in human beings. *N Engl J Med* 303: 322-324.
38. van Rees JB, de Bie MK, Thijssen J, Borleffs CJ, Schalij MJ, et al. (2011) Implantation-related complications of implantable cardioverter-defibrillators and cardiac resynchronization therapy devices: a systematic review of randomized clinical trials. *J Am Coll Cardiol* 58: 995-1000.
39. Reynolds MR, Cohen DJ, Kugelmass AD, Brown PP, Becker ER, et al. (2006) The frequency and incremental cost of major complications among Medicare beneficiaries receiving implantable cardioverter-defibrillators. *J Am Coll Cardiol* 47: 2493-2497.
40. Alter P, Waldhans S, Plachta E, Moosdorf R, Grimm W (2005) Complications of implantable cardioverter defibrillator therapy in 440 consecutive patients. *Pacing Clin Electrophysiol* 28: 926-932.
41. Borleffs CJ, van Erven L, van Bommel RJ, van der Velde ET, van der Wall EE, et al. (2009) Risk of Failure of Transvenous Implantable Cardioverter-Defibrillator Leads. *Circ Arrhythm Electrophysiol* 2: 411-416.
42. Rowley CP, Gold MR (2012) Subcutaneous implantable cardioverter defibrillator. *Circulation Arrhythm Electrophysiol* 5: 587-593.
43. Lewis GF, Gold MR (2016) Safety and Efficacy of the Subcutaneous Implantable Defibrillator. *J Am Coll Cardiol* 67: 445-454.
44. Bardy GH, Cappato R, Hood M, Rissmann RJ, Gropper CM, et al. (2002) The totally subcutaneous ICD system (the S-ICD) [abstract]. *Pacing Clin Electrophysiol* 25: 578.
45. Bardy GH, Smith WM, Hood MA, Crozier IG, Melton IC, et al. (2010) An entirely subcutaneous implantable cardioverter-defibrillator. *N Engl J Med* 363: 36-44.
46. Hauser RG (2013) The subcutaneous implantable cardioverter-defibrillator: should patients want one? *J Am Coll Cardiol* 61: 20-22.
47. Burke MC, Gold MR, Knight BP, Barr CS, Theuns DA, et al. (2015) Safety and efficacy of the totally subcutaneous implantable defibrillator: 2-year results from a pooled analysis of the IDE study and EFFORTLESS registry. *J Am Coll Cardiol* 65: 1605-1615.
48. Röger S, Borggrefe M, Kuschyk J (2015) Heart Failure with Reduced Ejection Fraction and a Narrow QRS Complex: Combination of a Subcutaneous Defibrillator with Cardiac Contractility Modulation. *J Atr Fibrillation* 8: 74-78.