

S. Chhabra^{1*} and Shweta Raman²¹Director Professor, Obstetrics & Gynaecology, Mahatma Gandhi Institute of Medical Sciences, Sevagram, Wardha – 442 102, Maharashtra, India²Ex Postgraduate Student, Obstetrics & Gynaecology, Mahatma Gandhi Institute of Medical Sciences, Sevagram, Wardha – 442 102, Maharashtra, India**Dates:** Received: 08 August, 2014; Accepted: 18 September, 2014; Published: 20 September, 2014***Corresponding author:** S. Chhabra, Director Professor, Obstetrics & Gynaecology, Mahatma Gandhi Institute of Medical Sciences, Sevagram, Wardha – 442 102, Maharashtra, India, E-mail: chhabra_s@rediffmail.com

www.peertechz.com

ISSN: 2455-5282

Case Report**Vesical Calculi with Utero Cervico Vaginal Prolapse****Abstract**

Vesical calculi are not commonly seen with utero vaginal prolapse. Calculi may be missed unless ultrasonography or X-ray is done. If not diagnosed problems can occur during surgery and post operatively. If vesical calculi are removed vaginally during anterior colporrhaphy, it may lead to fistula formation. Suprapubic cystostomy and removal of calculi done during vaginal surgery for genital prolapse seems better option. We present 3 cases which were managed within a span of 6 months with satisfactory results.

Introduction

Uterocervico vaginal prolapse and vesical calculi are two well known disorders; however their coexistence is not commonly seen. In clinical practice women with uterocervico vaginal prolapse do present with urinary complaints like difficulty, burning, frequency of micturition because of bladder trigone prolapse with the anterior vaginal wall with change in urethrovesical angle and collection of urine in the pouch below the urethral meatus. Calculi are not common and not thought of. Stasis does promote infection and stone formation. Infection is common but bladder stones uncommon. Bladder stone/stones may be detected during preoperative workup accidentally on ultrasonography.

We present three such cases managed over a short span.

Cases

Case one was a sixty years old woman who presented to gynaecological outpatient with complaints of something coming out of vagina since 5-7 years, vaginal bleeding and burning micturition since one year. She had four home births, last was 30 years back. She had attained menopause 15 years back. Second case was a 65 years old woman who presented with complaints of something coming out of vagina since one year, difficulty in passing urine since 6 months. She also had four home births, last 35 years back. She had menopause twenty years back. Third case was also 60 years old woman with complaints of something coming out of vagina, difficulty in passing urine and white discharge since five years. She had three home births, last 35 years back and had attained menopause 10 years back. They did not have chronic cough or constipation. There was no history suggestive of urinary calculi.

All three women were anaemic with no abnormality in other systems. First woman had procidentia, cystocele, rectocele with decubitus ulcer on the cervix with a small size mobile uterus and no abnormality in the fornices. Second woman had third degree uterocervical descent, cystocele and rectocele with cicatrized cervical os. Vaginal wall was thick and nodular and uterus was of small size. Utero cervical length, measured with difficulty was 7 cm. Third woman had procidentia with 4 cms size polypoidal growth

and ulceration on left lateral wall of vagina. Edge of the ulcer bled on touch. Uterus was of small size with cervix cicatrized. Vaginal malignancy was suspected. Routine investigations of all the cases were within normal limits. Abdomiopelvic ultrasonography (USG) revealed bilateral hydronephrosis in first two cases following which intravenous pyelography was done and vesical calculi were detected (Figures 1 and 2). In the third case multiple vaginal biopsies from ulceration and growth revealed well differentiated squamous cell carcinoma. Cystoscopy revealed cystitis with vesical calculus confirmed on intravenous pyelography (Figure 3). In first two cases surgery included vaginal hysterectomy with anterior and posterior colpo perineorrhaphy. Third case underwent vaginal hysterectomy with vaginectomy with anterior and posterior colpoperineorrhaphy with pelvic lymphadenectomy. In all the three vesical calculi were

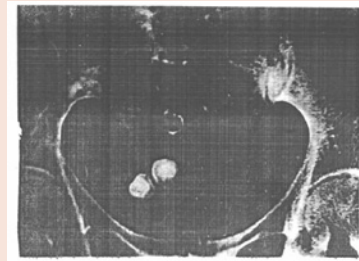


Figure 1:

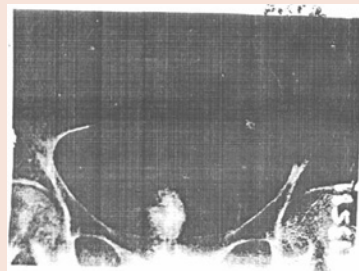


Figure 2:

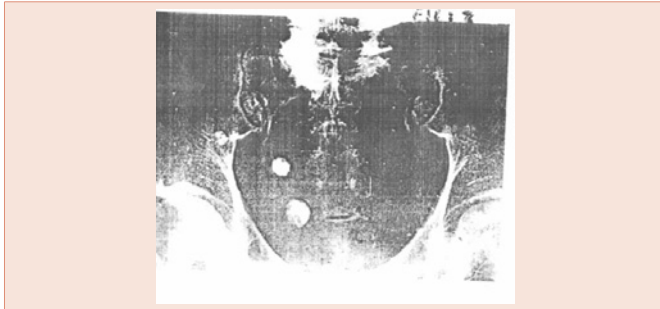

Figure 3:

removed through suprapubic cystotomy. Transvesical Malecot catheter, retropubic drain and transurethral Foley's catheter were inserted. Postoperative period was uneventful in all the three cases vesical calculi were removed through suprapubic cystotomy. Transvesical malecot catheter, retropubic drain and transurethral foley's catheter were inserted. Postoperative period was uneventful in all the three cases. Catheters were removed after two weeks followed by removal of the retropubic drain. Third case was put on chemotherapy.

There were no intraoperative or postoperative complications in any case and on follow up, 6 weeks, 3 months, 6 months.

Discussion

Vesical calculi can form in cases of stasis of urine because of calcium deposition over oxalate crystal sediments which leads to calcium oxalate stone formation. In women who have uterovaginal prolapse with cystocele, stones may be formed in the pouch formed by the bladder. Woman might remain asymptomatic. There might be symptoms which are believed to be because of uterocervicovaginal prolapse. Though cystocele is a common disorder, association with bladder calculi is uncommon [1]. Long-standing uterovaginal prolapse with bladder outlet obstruction, chronic infection can lead to stone formation. Calculi could be missed unless USG or Xray is done, as would have happened in the present series. In one case nodularity was felt in vagina. There was evidence of hydronephrosis on USG in two cases following which intravenous pyclography was done in all the cases which lead to diagnosis of bladder calculi.

The presence of bladder calculi should be considered in the setting of irreducible pelvic organ prolapse. Siriwardana [1] and Dahiya [3] reported that in case of occurrence of acute irreducible pelvic organ prolapse or incarceration of procidentia, the possibility of bladder stones must be kept and confirmed by X-ray.

The missed calculus prior to surgery for prolapse could lead to complications due to persistence and progressive damage, another sitting of surgery, anaesthesia and operative difficulties.

If calculus is removed by vaginal route during anterior colporrhaphy, there is risk of fistula formation. Suprapubic cystotomy seems a better way and should cure the patient completely with no risk of fistula formation. Abdomino-vaginal surgery should preferably be done simultaneously, as distending the bladder for cystotomy after completing anterior colporrhaphy may lead to disruption of vaginal suture line. Postoperatively there should be no haste in removing catheter and drains to promote healing especially in elderly women in whom prolapse is common. Infection needs to be prevented.

Earlier a case of vesical calculus causing obstructed labour has been reported [4]. Though many cases of uterovaginal prolapse are managed, association with bladder calculus has not been seen commonly. Cases with long standing procidentia having hydronephrosis with renal failure due to ureteric kinking have been seen. On review of literature, report cases of bladder, calculi are scarce. Three cases in a span of six months in this rural institute was a real surprise, so we thought of sharing our experiences of management challenges.

References

1. Singal R, Goyal S, Sekhon MS, Pandit S (2010) A rare giant urinary bladder stone: a case report. *Urotoday Int J* 3.
2. Siriwardana PN, Gunasekara M (2008) Multiple vesical calculi in a cystocele: an uncommon complication of procidentia. *J Pelvic Med Surg* 14: 207-208.
3. Dahiya P, Gupta A, Sangwan K (2007) Multiple bladder calculi: a rare cause of irreducible uterine prolapse. *Arch Gynecol Obstet* 275: 411-412.
4. Chhabra S (1986) Vesical calculus complicating labour. *The Journal of Obstetrics and Gynaecology of India* 36: 545.
5. Johnson CG (1958) Giant calculus in the urinary bladder associated with complete uterine prolapse; report of a case. *Obstet Gynecol* 11: 579-580.
6. Dongol A, Joshi KS, KCS (2013) Renal Impairment Among Patients with Pelvic Organ Prolapse in a Tertiary Care Center. *Kathmandu Univ Med J* 41: 71-74.