

Awad Ali M Alawad^{1*} and Mohamed D Gismalla²

¹Department of Surgery, University of Medical sciences and Technology, Sudan

²Department of Surgery, University of Gezira, Sudan

Dates: Received: 01 August, 2015; Accepted: 12 August, 2015; Published: 14 August, 2015

*Corresponding author: Awad Ali Mohamed Ahmed Alawad, Department of Surgery, University of Medical Sciences and Technology, Sudan, Tel: 00249912802545; E- mail: awadali82@hotmail.com

www.peertechz.com

ISSN: 2455-5282

Keywords: Skeletal muscle tuberculosis; Intramuscular abscess; Antituberculous drugs therapy

Case Report

Tuberculous Abscess of the Anterior Abdominal Wall: An Unusual Site of Presentation

Abstract

The skeletal muscles are rarely affected by tuberculosis because they are not a favorable site for the survival and multiplication of *Mycobacterium tuberculosis*. A case of tuberculous abscess in rectus abdominis muscle is described in a 20- year- old female in an apparently healthy individual without any past history of tuberculosis. The diagnosis was made by ultrasound-guided fine-needle aspiration and cytological examination which revealed caseating granuloma with central necrosis, lymphocytes, and giant cells, consistent with tuberculosis. After four weeks' antituberculous treatment, she responded well and the abscess regressed considerably. In most cases, the muscle involvement is secondary and is caused by either hematogenous route or direct inoculation from a tuberculous abdominal lymph node or extension from underlying tubercular synovitis and osteomyelitis. This case cautions the clinicians and radiologists about the possibility of tuberculosis in considering the differential diagnosis of any lesion even in any unlikely anatomical area, especially in those areas where tuberculosis is endemic.

Introduction

The skeletal type of muscles are rarely affected by tuberculosis (TB) because they are not a preferred site for the survival and multiplication of *Mycobacterium tuberculosis* [1]. Even in patients with widespread involvement by the disease, tuberculosis rarely involves muscles. Petter et al. recorded only one case of primary skeletal muscles tuberculosis in over 8,000 cases of all types of tuberculosis, with an incidence of 0.015% [2]. Few cases of tubercular myositis have been described in literature till now, mostly in the adults. This, together with the decline in tuberculosis in general, makes it unlikely that one would immediately consider tuberculosis as the cause of rectus sheath abscess.

There are only limited cases reports of isolated tubercular involvement of the anterior abdominal wall even though tuberculosis is a rampant in developing countries and with the rapid spread of acquired immune deficiency syndrome (AIDS) it has made inroads into the developed nations as well [3]. We are presenting a case of primary tuberculous abdominal wall abscess without any evidence of pulmonary, skeletal or gastrointestinal tuberculosis in an immune competent patient. This case report should serve as a reminder that tuberculosis, in all of its various manifestations, is still very much among us.

Case Report

A 20-year-old female presented to the outpatient department of surgery, with a complaint of a progressive swelling in the left lower abdomen for the last three months. There was no history of preceding trauma, fever, cough, malaise or pain. There was no history of contact with any case of tuberculosis. On examination, there was swelling in the left iliac fossa measuring 8x8cm in size, non-tender with smooth and ill-defined margins and a normal overlying skin. The swelling was firm in consistency and moved with respiration. Examinations of the cardiovascular and respiratory system were within normal limits.

Laboratory investigation revealed: hemoglobin 11.5 g/dl; total leukocyte count 8510/cumm with a differential count of 54% neutrophils, 42% lymphocytes and 4% eosinophils; Erythrocyte Sedimentation Rate 70 mm and ELISA for HIV negative. The chest radiograph was unremarkable. Other biochemical blood investigations were within normal limits. Ultrasonography of the abdomen revealed a 6.5x8.5cm left iliac fossa cystic mass with a liquefied necrotic center in the anterior abdominal wall (Figure 1). Computerized Tomography scan of the abdomen showed an abscess in the left antero-lateral portion of the abdominal wall limited to the muscle layer (Figure 2). Ultrasound-guided fine-needle aspiration and cytological examination revealed caseating granuloma with central necrosis, lymphocytes, and giant cells, consistent with tuberculosis (Figure 3). The patient was diagnosed to have tuberculous abscess of the anterior abdominal wall and antituberculous treatment was started. She improved rapidly over the next few days. After four weeks' antituberculous treatment (ATT), she responded well to the

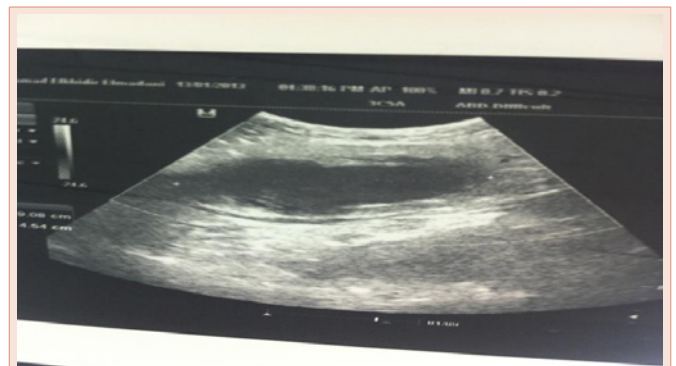

Figure 1: Ultrasonography of the abdomen revealed a left iliac fossa cystic mass.

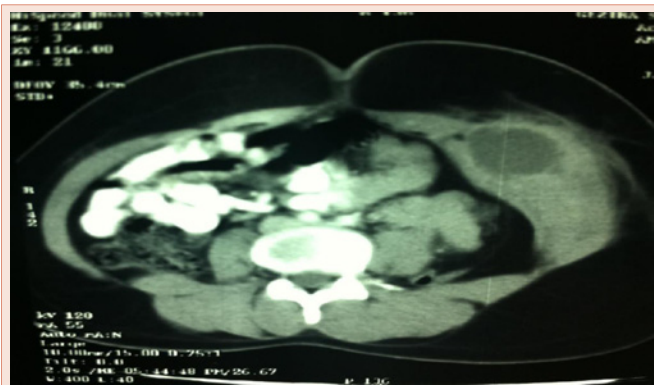


Figure 2: Focal cystic collection seen in the anterior abdominal wall of the left iliac fossa with mild peripheral enhancement (white arrow).

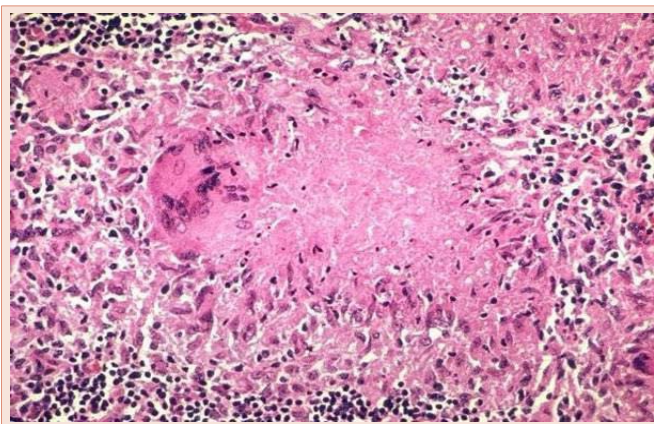


Figure 3: Photomicrograph revealed caseating granuloma with central necrosis, lymphocytes, and giant cells, consistent with tuberculosis.

treatment and the abscess regressed considerably. ATT was continued for 9 months.

Discussion

Tuberculosis of the anterior abdominal wall is a rare entity and only isolated cases are reported in the literature. The possible explanation for the rarity of muscle involvement in tuberculosis may be high lactic acid content, lack of reticulo-endothelial tissue in muscle, lack of lymphatic tissue, the abundant blood supply and the highly differentiated state of muscle tissue [4]. Although none of them seems to be an adequate explanation, all theories, except the first one, have been criticized [2].

Two forms of skeletal muscle involvement are recognized [5]: In the first type the tuberculous process spreads into the muscle through direct extension from a neighboring structure e.g. bone, joint, tendon, and lymph node. In the second type the spread is hematogenous. Our patient is of interest because he seems to have a primary tubercular

anterior abdominal muscular lesion without any evidence of immune incompetence.

A tuberculous focus in the muscle usually manifests as progressive swelling and pain. The infection is usually restricted to one muscle [6]. There may either be a frank tuberculous abscess (as seen in our case) or a nodular sclerosis followed by calcification. Ultrasonography usually shows a cystic mass of mixed echogenicity with irregular walls and a liquefied, necrotic center. Computed scan of the abdomen usually shows a well-defined abscess in the abdominal wall [7,8]. Ultrasonography or CT-guided aspiration followed by cytological examination usually reveals tuberculous granulomas with areas of caseous necrosis.

Management of this entity is mainly in the form of antituberculous drugs. Surgical intervention in the form of either sonography or CT-guided aspiration or open drainage is usually reserved to patients in whom medical treatment fails [3]. Our patient responded well to medical treatment.

Although localized swelling in the rectus abdominis muscle is commonly due to necrotizing fasciitis, rectus sheath hematoma or tumors (benign / desmoid/ malignant), a rare possibility of tuberculosis should also be considered. The prognosis is good in tuberculous myositis with appropriate chemotherapy.

Conclusion

This case cautions the clinicians and radiologists about the possibility of tuberculosis in considering the differential diagnosis of any lesion even in any unlikely anatomical area, especially in those areas where tuberculosis is endemic.

References

1. Sabat D, Kumar V (2009) Primary tuberculous abscess of rectus femoris muscle: a case report. *J Infect Dev Ctries* 3: 476-478.
2. Malhotra MK (2012) Cold abscess of the anterior abdominal wall: an unusual primary presentation. *Niger J Surg* 18: 22-23.
3. Rebai W, Chebbi F, Bouassida M, Azouz H, Ksantini R, et al. (2010) [Tuberculosis of the abdominal wall: a rare localization]. *Med Trop (Mars)* 70: 6.
4. Desai N, Patil S, Thakur BS, Das HS, Manjunath SM, et al. (2003) Abdominal wall abscess secondary to subcapsular tubercular liver abscess. *Indian J Gastroenterol* 22: 190-191.
5. Saika A, Kanno T, Ishiguchi T, Oka H, Shiotani A, et al. (1997) [A case of the tuberculous abscess in the abdominal wall]. *Kansenshogaku Zasshi* 71: 540-544.
6. Abid M, Ben Amar M, Abdenadher M, Kacem AH, Mzali R, et al. (2010) [Isolated abscess of the thoracic and abdominal wall: an exceptional form of tuberculosis]. *Rev Mal Respir* 27: 72-75.
7. Yilmaz T, Sever A, Gur S, Killi RM, Elmas N (2002) CT findings of abdominal tuberculosis in 12 patients. *Comput Med Imaging Graph* 26: 321-325.
8. Sinan T, Sheikh M, Ramadan S, Sahwney S, Behbehani A (2002) CT features in abdominal tuberculosis: 20 years experience. *BMC Med Imaging* 2: 3.

Copyright: © 2015 Alawad AAM, et al. This is an open-access article distributed under the terms of the Creative Commons Attribution License, which permits unrestricted use, distribution, and reproduction in any medium, provided the original author and source are credited.

Citation: Alawad AAM, Gismalla MD (2015) Tuberculous Abscess of the Anterior Abdominal Wall: An Unusual Site of Presentation. *Global J Med Clin Case Reports* 2(1): 008-009. DOI: 10.17352/2455-5282.000017