



Alexandria Dennison^{1*}, Nafisha Ali¹ and Ahmed Ibrahim²

¹Medical Student, Department of Medicine, International American University School of Medicine, USA

²MD, FACP, Physician, Department of Medicine, Northwest Hospital, USA

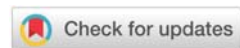
Received: 29 April, 2019

Accepted: 19 June, 2019

Published: 20 June, 2019

*Corresponding author: Alexandria Dennison, Medical Student, Department of Medicine, International American University School of Medicine, USA, Tel: 813-787-9831; E-mail: adennison@iau.edu.lc

<https://www.peertechz.com>



Case Study

No Underlying Cause: A Case of a Fatal Neuroendocrine Lung Tumor

Abstract

A 34 year old female with metastasizing neuroendocrine lung carcinoma with no underlying etiologies. Patient was diagnosed with stage 4 lung neuroendocrine cancer with treatment options limited due to intellectual disability and overall poor prognosis. The patient had a rapid decline over a 5 week period with decreased intake, decreased appetite, and overall azotemia and resulted in patient's death.

Introduction

This case highlights a rare lung neuroendocrine malignancy in a 34 year old female. The patient had a rapid decline within 5 weeks and had very limited treatment options. The aim in presenting this case is to bring attention to the high mortality rate of such an aggressive lung tumor, and the need for early diagnosis and improved subtyping of the tumors, as well as improved treatment options in hopes of saving lives of patients who receive this diagnosis.

Case Presentation

A 34 year old African American female presented to the emergency room accompanied by caregiver, in mild respiratory distress with a productive cough for the past 24 hours. Prior to examination, caregiver explained that the patient complained of a cough productive of sputum and difficulty breathing over the course of one week. She had visited many outpatient clinics over a 2 month period and was given a course of Bactrim for presumptive pneumonia, which patient completed without any signs of resolution of her pneumonia. A course of Azithromycin was then given however her symptoms remained unresolved. On physical examination, patient had a fever of 37.8 degrees Celsius (100.04 F), respiratory rate of 28 breaths per minute after administration of ipratropium-albuterol, and a heart rate of 112 bpm. She was admitted to telemetry for tachycardia and possible underlying pneumonia with pleural effusion.

Patient was started on a 5 day course of Levofloxacin 750 mg IV Qday infused over 90 mins for CrCl greater than or equal to 50 ml/min as routinely indicated for HCAP/HAP, Albuterol

1 neb inhaled Q4H PRN or shortness of breath/wheezing, Albuterol-ipratropium 3 ml inhaled Q4H for shortness of breath and wheezing, and benzonatate 200 mg 2 capsules PO TID, codeine-guaifenesin 10 ml PO Q4H, fluticasone 2 nasal sprays per nare, and montelukast 10 mg 1 tab PO QDay. She was also maintained on clozapine 300mg 3 tabs PO BID, benzotropine 1mg 1 tab PO TID, divalproex sodium 250mg 1 tab PO TID, levetiracetam 250mg 1 tab PO BID, ferrous sulfate 325 mg 1 tab PO QDay, and quetiapine 200mg 1 tab PO Qbedtime throughout her stay.

Physical examination on presentation yielded only an elevated heart rate, but a couple days later, yielded wheezing and dullness to percussion at multiple sites throughout the left lung. Patient's CBC on presentation were most remarkable for hypokalemia, leukocytosis (WBC 14.48 K/MM³), anemia (Hemoglobin 7.8 G/DL), and hypoalbuminemia. Hemoglobin A1c was 6.2.

At this point the patient had completed 3 courses of antibiotics with no resolution to her pneumonia symptoms. She has a strong medical history of multiple episodes of Upper and Lower Respiratory Tract Infections along with Bronchial Asthma with multiple Acute Exacerbations. Other pertinent past medical history included Eczema, Allergic Contact Dermatitis, Seborrheic Dermatitis, Cutaneous Candidiasis, Anemia, Intellectual Disability, Schizophrenia, and Seizure Disorder. Patient is unemployed, and family history is unavailable as patient resides in a group home as a result of years of multiple psychiatric co-morbidities. She is a lifelong non-smoker of tobacco, and denies illicit drug use or alcohol consumption. Patient was up to date on all vaccines including dTAP and Inactivated Influenza vaccines. Patient has no known drug allergies.

As per protocol, rate of resolution of her pneumonia was inappropriate and a thoracic CT was done, which demonstrated a large upper lobe lung mass measuring 11.3cm x 8.3cm x 9.6cm that was compressing the left pulmonary arteries and occluding portions of the left-sided mainstem bronchus, along with ill-defined masses in lower anterior left hemithorax, a left adrenal mass, and an intermediate nodule posterior to the left kidney. There was a large left and a small right pleural effusion. No pulmonary embolus was detected. The following week the patient had a needle core biopsy of the left upper lobe mass which showed a poorly differentiated neuroendocrine carcinoma with a pleomorphic population of large tumor cells with abundant mitotic activity and large areas of necrosis. The cells expressed (pan) cytokeratin, synaptophysin, chromogranin A, CD56 and partial, weak staining for TTF-1 on immunohistochemical staining. Ki-67 staining demonstrated a high proliferation index (>80%). Pleural fluid cytology report from left sided thoracentesis showed metastatic poorly differentiated neuroendocrine carcinoma with tumor cells that were morphologically similar to those seen in the lung biopsy. Repeat thoracic CT that week demonstrated near complete occlusion of the left mainstem bronchus.

GI was consulted to rule out underlying GI bleed and patient's anemia was decided to be secondary to malignancy and advised transfusion of one unit packed RBCs. ID considered the patient to have post-obstructive pneumonia, for which she received multiple courses of antibiotics prior to cultures and sensitivity results returning negative, after which antibiotics were stopped. Cardiothoracic surgery and hematology and oncology were consulted and it was decided that, based on pleural involvement, the neuroendocrine carcinoma was unresectable. Prior to her hospitalization the patient had a very poor oral intake, lack of appetite, and overall poor functional status. The patient's failure to thrive (FTT) was ruled to be due to her malignancy. She now had decreased energy, signs of depression, and increased fatigue. It was decided that the patient would be unable to tolerate systemic cisplatin-based dual combination regimen chemotherapy, as is standard for neuroendocrine carcinoma of the lung. Patient continued to have coughing spells despite having undergone thoracentesis twice to remove fluid. Two weeks after admission, the patient was transferred to another hospital within the same system where she received five days of palliative radiation followed by hospice care with comfort measures due to the patient's diagnosis of failure to thrive. The patient continued to rapidly decline and passed approximately 1 month after her initial admission.

Discussion

The incidence of Neuroendocrine Carcinomas (NECs) of the Lung in the United States ranged from 1.49 per 100,000 population per year between the years 2000-2012 [1]. The majority of neuroendocrine tumors are sporadic, with no clear association with smoking or other environmental or genetic risk factors, however, some NECs are associated with Multiple Endocrine Neoplasia Type 1 [2].

Generally, neuroendocrine tumors (NETs) are malignancies that arise from neuroendocrine cells and occur most commonly in the lungs or the gastrointestinal tract. There are 4 main types of lung neuroendocrine tumors: poorly differentiated, high-grade SCLCs (20%); poorly differentiated, high-grade large cell neuroendocrine carcinomas (LCNECs) (3%); well-differentiated, low-grade typical carcinoids (TCs) (2% of primary lung neoplasms); and well-differentiated, intermediate-grade atypical carcinoids (ACs) (<1%)[3,4]. Typical NETs are approximately four times more common than Atypical NETs; with Typical NETs having a low mitotic rate compared to Atypical NETs which have a higher mitotic rate and/or necrosis [2].

Common signs and symptoms of patients presenting with a neuroendocrine lung tumor include a cough, wheeze, chest pain, and hemoptysis. Some patients usually experience recurrent pneumonia localized to the same area of the lung as the tumor, resulting in patients receiving multiple courses of antibiotics before the tumor is properly diagnosed.

Diagnosis is achieved using highly sensitive computed tomography (CT) imaging which aids in locating the tumor. Seventy-five percent of neuroendocrine lung tumors are centrally located [2]. CT is followed by bronchoscopic biopsies for central lesions, or by transthoracic needle biopsy for peripheral lesions [2]. Biopsy analysis confirms the diagnosis.

Using immunohistochemistry to identify cytoplasmic products such as chromogranin, neuron-specific enolase, and synaptophysin confirm diagnosis of NEC, with 50 percent of lung neuroendocrine tumors staining positive for thyroid transcription factor 1 (TTF1) [5,6]. Presence or absence of necrosis, and number of mitoses per 2mm² of viable tumor sample helps to differentiate the subtype of lung NET [4]. TCs have <2 mitoses per 2mm² and no necrosis; ACs have 2-10 mitoses per 2mm² or necrosis; SCLC has >10 mitoses per 2mm² with cytological features of SCLC; and LCNECs have >10 mitoses per 2mm² with cytological features of LCNECs [4,7]. It must be noted that histopathological differences between subtypes can be very subtle, allowing room for notable differences in opinion between individual observers.

The preferred treatment option for patients with NETs is surgical resection as long as the patient has adequate pulmonary reserve. Patients may also undergo transbronchoscopic resection if lesions are low-grade and entirely endobronchial. For patients with histologically aggressive-looking, Stage III, atypical NETs, platinum-based chemotherapy with or without radiation therapy may be considered as a viable alternative, however, there is no evidence to support this alternative [8]. There is also not enough research on whether radiation therapy improves outcomes post-operatively for atypical lung neuroendocrine tumor following surgical resection.

Conclusion

The guidelines for diagnosis and management of lung neuroendocrine tumors is not fully established. There is also

a lack of known risk factors that aid in achieving an early diagnosis or implementing preventative measures. Our patient was initially suspected of having pneumonia based on her history of multiple upper respiratory tract infections. Two courses of antibiotics provided no resolution to her cough after two months. Based on CT scan impression, the next best step in management was to have a biopsy of the mass along with thoracentesis. The main concern for this patient was her rapid decline. Treatment options for this patient were limited not only by her intellectual disability, late stage diagnosis, and size and metastasis of her tumor, but also due to the fact that her tumor could not be subtyped based on the current WHO 2015 recommendations for classification of NETs. It was therefore in the best interest of the patient to provide comfort care.

Further research is needed to aid in categorizing a wider spectrum of neuroendocrine lung carcinomas whereby allowing a reduction in variability of opinions on histopathology, which is essential for subtyping these tumors and narrowing treatment regimens. There continues to be little evidence that chemotherapy and radiation are the best treatment options. It is recommended that further research be put into improving subtype classes and treatment options in order to improve quality of life of patients who receive this diagnosis.

References

1. Dasari A, Shen C, Halperin D (2017) Trends in the Incidence, Prevalence, and Survival Outcomes in Patients With Neuroendocrine Tumors in the United States. *JAMA Oncol* 3: 1335-1342. [Link: https://bit.ly/2ZAkeUd](https://bit.ly/2ZAkeUd)
2. Thomas C, Jett J, Strosberg J (2018) Lung neuroendocrine (carcinoid) tumors: Epidemiology, risk factors, classification, histology, diagnosis, and staging. *UpToDate*. [Link: https://bit.ly/2x1zMUN](https://bit.ly/2x1zMUN)
3. Rekhtman N (2010) Neuroendocrine tumors of the lung: an update. *Arch Pathol Lab Med* 134: 1628-1638. [Link: https://bit.ly/2XXNWIL](https://bit.ly/2XXNWIL)
4. Travis WD, Brambilla E, Burke AP, Marx A, Nicolson AG (2015) WHO Classification of Tumours of the Lung, Pleura, Thymus and Heart. 4th ed. Lyon, France: International Agency for Research on Cancer.
5. Gustafsson BI, Kidd M, Chan A (2008) Bronchopulmonary neuroendocrine tumors. *Cancer* 113: 5-21. [Link: https://bit.ly/2lpo1x0](https://bit.ly/2lpo1x0)
6. Saqi A, Alexis D, Remotti F, Bhagat G (2005) Usefulness of CDX2 and TTF-1 in differentiating gastrointestinal from pulmonary carcinoids. *Am J Clin Pathol* 123: 394-404. [Link: https://bit.ly/2ZwEjL3](https://bit.ly/2ZwEjL3)
7. Travis WD (2014) Pathology and diagnosis of neuroendocrine tumors: lung neuroendocrine. *Thoracic Surg Clin* 24: 257-266. [Link: https://bit.ly/2ZuSJeP](https://bit.ly/2ZuSJeP)
8. Thomas C, Jett J, Strosberg J (2018) Lung neuroendocrine (carcinoid) tumors: Treatment and prognosis. *UpToDate*. [Link: https://bit.ly/2IXJBZx](https://bit.ly/2IXJBZx)