

Tariq Yehia Abdelrahman Mohamed Yehia^{1*}, Salma El-Ashry², Kareem El-Batoty² and Soha El-Hady³

¹Faculty of Dentistry, Ain Shams University, Abassia, Cairo, Egypt

²Professor of Endodontics, faculty of Dentistry, Alain Shams University, Egypt

³Professor of medical microbiology & immunology, faculty of Medicine, Alain Shams University, Egypt

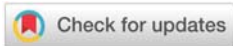
Received: 02 May, 2019

Accepted: 01 August, 2019

Published: 02 August, 2019

***Corresponding author:** Tariq Yehia Abdelrahman Mohamed Yehia, Faculty of Dentistry, Ain Shams University, Department of Endodontics, Abassia, Cairo, Egypt, Tel: 002-01005115858; E-mail: tariqyehia@asfd.asu.edu.eg

<https://www.peertechz.com>



Research Article

Efficiency of Triple Antibiotic Mixture and Propolis as Intracanal Medication in Revascularization process in immature apex: A clinical study

Abstract

Introduction: The aim of this clinical study was to evaluate the effect of different antibacterial combinations on the outcome of revascularization process in permanent anterior immature teeth.

Methods: Immature necrotic permanent maxillary incisors (n = 40) of patients 8–18 years old were divided into 4 groups according to the intracanal medicament: group 1 was treated with Triple Antibiotic Paste (TAP), group 2 was treated with Ciprofloxacin + Propolis paste (CP), group 3 was treated with Ciprofloxacin + Metronidazole paste (CM), group 4 was treated with Propolis + Metronidazole paste (PM). Cases were followed at regular intervals up to 18 months clinically and radiographically.

Results: All cases showed radiographic evidence of periapical healing and continued root development. No statistically significant difference in root length, thickness, apical closure or periapical density between all groups through the whole follow up period.

Conclusion: Propolis is successful substitute for ciprofloxacin or metronidazole in DAP for effective disinfection in revascularization process.

Introduction

In the last 10 years, numerous published cases and case series described the revascularization or regenerative endodontics. Revascularization is a conservative method for inducing maturogenesis in necrotic immature teeth [1]. The favorable outcomes of regenerative endodontics are largely dependent on the adequate disinfection of the root canal [1]. These canals with compromised fragile underdeveloped dentinal walls represent a contraindication for mechanical instrumentation; thus, chemical debridement remains the main form of disinfection [1]. A mixture of ciprofloxacin, metronidazole, and minocycline, known as the triple antibiotic paste (TAP), has been shown to be very effective in eliminating endodontic pathogens in vitro and in situ [1,3–5]. However, TAP has an adverse effect on stem cell survival [6]. Discoloration of the tooth is a problem mostly related to the use of minocycline in TAP [7]. Moreover, TAP can demineralize dentin resulting in reduced microhardness and fracture resistance [8]. Propolis, a flavonoid-rich resinous product of honeybees, is ten times less cytotoxic than calcium hydroxide and has a well-known antibacterial effect [9]. Therefore, creating alternatives to the

TAP for disinfecting the root canal of necrotic teeth during the process of pulp revascularization is thought to be of value. The null hypothesis in the current study stated that there is no difference between the tested intracanal medications on the outcome of the revascularization process in immature teeth.

Materials and Methods

Forty patients with immature, non-vital maxillary incisors were included in this study from the outpatient clinic of the Faculty of Dentistry, Ain Shams University, Cairo, Egypt. A detailed medical and dental history was obtained from each patient's parents or guardians. Only medically free patients were included in this research. The clinical and radiographic exclusion criteria were teeth with vertical fractures, periodontally involved teeth, and nonrestorable teeth. All procedures were performed after obtaining proper institutional review board approval based on the regulations of the Ethical Committee of the Faculty of Dentistry, Ain Shams University (FDASU-REC1011508). Intraoral periapical radiographs revealed immature apices. The age of the patients ranged between 8 and 18 years. Informed consent was signed for

each case by the patient's parents or guardians including the proposed treatment and possible outcomes or complications.

Cases were divided randomly and equally into 4 groups according to the intracanal medicament (10 patients for each group):

TAP group: was treated with Triple Antibiotic Paste

CP group: was treated with Ciprofloxacin + Propolis paste

CM group: was treated with Ciprofloxacin + Metronidazole paste

PM group: was treated with Propolis + Metronidazole paste

1). Triple Antibiotic Paste (TAP): It consisted of Ciprofloxacin (Ciprocin 250 mg tablets; EPICO, Cairo, Egypt), Metronidazole (Flagyl 500 mg tablets; Sanofi Aventis Pharma, Cairo, Egypt), Doxycycline (Vibramycin 100 mg capsules; Pfizer, Cairo, Egypt). One Doxycycline capsule content was evacuated in a sterile mortar, one tablet of metronidazole and one tablet of ciprofloxacin were crushed and ground in the same mortar using a pestle into homogenous powder. Saline drops (Otrivin baby saline; Novartis, Cairo, Egypt) were added and mixed using the pestle until a creamy paste was achieved [4,10].

2). Ciprofloxacin + Propolis Paste: Ethanol extract of raw propolis (EEP; ElEzaby Co. Labs, Cairo, Egypt.) was prepared by adding 10 gm of propolis (Imtinan, Cairo, Egypt) to 40 gm of 70% ethanol (ElGomhorya Co., Cairo, Egypt) (for 20% tincture) in a dark container to prevent reduction of propolis. The container was sealed and placed at room temperature for a period of three weeks. The sealed container was manually shaken every 2 days to ensure proper mixing. After 3 weeks, the container was opened and ethanol extract of propolis was obtained. Ethanol-free EEP was made by evaporating the ethanol in a water bath [11,12]. EEP was then mixed with Ciprofloxacin powder in the ratio 1:1. Saline drops were added and mixed using the pestle until a creamy paste was achieved.

3) Ciprofloxacin + Metronidazole Paste: Ciprofloxacin powder was mixed with Metronidazole powder in the ratio 1:1. Saline drops were added and mixed using the pestle until a creamy paste was achieved.

4) Propolis + Metronidazole paste: EEP was mixed with Metronidazole powder in the ratio 1:1. Saline drops were added and mixed using the pestle until a creamy paste was achieved.

A preoperative radiograph was taken using the standardized paralleling technique by the Rinn XCP alignment system (Rinn Corporation Elgin, Illinois, USA) and Fona ScaNeo intra-oral digital imaging system (FONA Dental, Bratislava, Slovak Republic). Patients were treated as follows: Caries was excavated; access cavity was prepared. The rubber dam was then applied and working length was determined with a periapical radiograph taken with a file inserted into the canal. Canal space was debrided using K file size #80. Canal space was irrigated using 40 cc of NaOCl 2.6% solution and final flush of saline. Canal space was dried using paper points. The antibiotic paste was prepared as previously described. One

cubic centimeter of the prepared paste was injected into the canals using a sterile plastic syringe with 20" gauge needle. Care was taken to avoid apical extrusion and to minimize placement in the coronal portion of the tooth. The access cavity was then sealed using temporary restoration (Coltosol F; Coltene Whaledent, Altstatten, Switzerland) over plain cotton. Coltosol F is a long-term temporary restoration. After the 3 weeks, under the same aseptic conditions, anesthesia without vasoconstrictor (Mepecaine, Alexandria Co., Alexandria, Egypt) was administrated. The tooth was re-entered, the antibiotic paste was removed and the canal was irrigated using a sterile saline and dried using paper points [4,13].

Sterile hand file size #25 was introduced into the root canal and placed at 2 mm beyond the working length to induce bleeding into the canal. The bleeding was allowed to reach a 3-mm level below the cemento-enamel junction, and teeth were left at rest for 5 minutes so that a blood clot could be formed [14]. Next, a 3-mm plug of MTA (Angelus; Londrina, Brazil) was inserted into the canals using a suitable-sized amalgam carrier to seal the root canal at the cervical level. The MTA plug was verified radiographically. The MTA plug was then covered by moist cotton and temporary filling. After one week, MTA setting was confirmed clinically, adhesive composite resin (Z250 Restorative; 3M ESPE, St Paul, Minnesota, USA) was used to seal the access cavity [15-17] Figure 1.

Evaluation:

Patients were recalled for follow up at 3, 6, 9, 12, and 18 months. Follow-up included the clinical assessment of pain and/or swelling, and standardized radiographic assessment for:

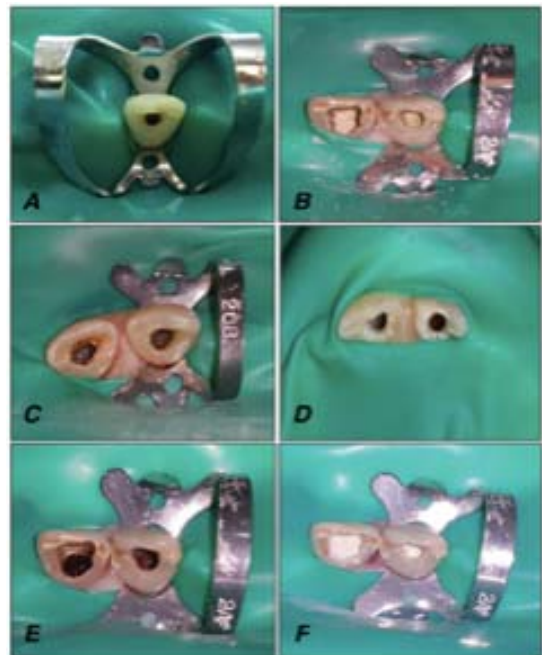


Figure 1: Photographs showing the clinical steps of pulp revascularization; A) after cleaning and irrigation with NaOCl solution, B) after intracanal application of TAP or CM, C) after intracanal application of CP or PM, D) dry clean canals after removal of intracanal medication, E) blood clot induced up to the level of canal orifice, F) MTA orifice plug.

1. An increase in root length
2. An increase in root thickness
3. A decrease in apical diameter
4. A change in periapical bone density

All follow-up radiographs were standardized using the Rinn XCP alignment system and Fona ScaNeo intra-oral digital imaging system. All radiographic measures were collected by the same investigator. All radiographic measurements were repeated after 1 week, and the mean of the 2 sets was considered as the final value.

Increase in root length: A measuring scale was set in the Image-J software (Image-J v1.44, US National Institutes of Health, Bethesda, MD) by measuring a known clinical dimension to its radiographic dimension. The scale was calculated as number of measured pixels per mm length. Root length was measured as a straight line from the cemento-enamel junction to the radiographic apex of the tooth [4,18] in millimeters. Pre and follow-up root lengths were measured using Image-J analysis software. Difference in length was calculated. Percentage of increase in length was calculated as follows: percentage of increase in length = [(postoperative length – preoperative length) / preoperative length] x 100.

Increase in root thickness: Using the preset measurement scale, the level of the apical third was determined and fixed from the cemento-enamel junction. The root thickness and the pulp width were measured mesiodistally at this level in millimeters. Mesiodistal dentin thickness was measured by subtraction of the pulp space from the whole root thickness. Pre and follow-up root thicknesses were measured. Measurements were done pre and post operatively at the same fixed level [18]. Difference in dentin thickness was calculated. Percentage of increase in dentin thickness was calculated as follows: percentage of increase in dentin thickness = [(postoperative thickness – preoperative thickness) / preoperative thickness] x 100.

Decrease in apical diameter: Using the preset measurement scale, the mesiodistal diameter of the apical foramen was measured in millimeters [4]. Measurements were done pre and postoperatively. Percentage of apical closure was calculated as follows: percentage of apical closure = [(preoperative apical diameter – postoperative apical diameter) / preoperative apical diameter] x 100.

Periapical bone density: Periapical bone density was estimated using Image-J software as follows: periapical area was located and analyzed for bone density. Average area density was measured in scale from 0 (black) to 255 (white) and recorded for each radiograph. The same area was then measured in subsequent radiographs and average densities were recorded for the follow up radiographs [4]. The difference between densities was calculated between subsequent radiographs [4,5]. Percentage of change in density was calculated from the original pre-operative radiograph density as follows: percentage of change in density = [(postoperative bone density – preoperative bone density)/preoperative bone density] x 100.

Data were collected, tabulated and statistically analyzed using statistical analysis software SPSS (Statistical Packages for the Social Sciences 19.0, IBM, Armonk, NY). Two-way analysis of variance was performed. The Tukey post hoc test was used in case of significance.

Results

A total of five cases were dropped out from the study, four of which was excluded due to poor patient compliance. Clinical and radiographic examination during the follow-up period showed signs and symptoms of failure in 1 case, which was re-evaluated, and the treatment plan was shifted to MTA apexification. Clinical outcomes are presented in Table 1.

Radiographic changes:

I. Increase in root length: Figure 2

- Effect of type of intracanal medication:

Statistical analysis revealed significant effect of time on increase in root length. However, no statistically significant difference was found between 3 months and 6 months, nor between 6 months and 9 months, nor between 9 months and 12 months (P > 0.05) Table 2

- Effect of time:

Statistical analysis revealed significant effect of time on increase in root length. However, no statistically significant difference was found between 3 months and 6 months, nor between 6 months and 9 months, nor between 9 months and 12 months (P > 0.05) Table 2.

II. Increase in root thickness: Figure 3

- Effect of type of intracanal medication:

Statistical analysis showed that there was no statistically significant difference between all groups through the whole follow up period (P > 0.05) Table 3. Effect of time:

No statistically significant difference was found between 6 months and 9 months (P > 0.05). However, statistically significant difference was found among other follow up periods Table 3.

Table 1: The percentage of cases which presented clinical signs and symptoms after the revascularization visit.

Intracanal medication	Postoperative pain/discomfort	Swelling	Sensitivity to percussion	Sensitivity to palpation	+ve response to thermal test	Functional asymptomatic tooth
TAP (Group 1)	40 %	0 %	0 %	0 %	0 %	100 %
DAP-1 (Group 2)	20 %	0 %	0 %	0 %	0 %	100 %
DAP-2 (Group 3)	20 %	0 %	0 %	0 %	0 %	100 %
DAP-3 (Group 4)	30 %	0 %	0 %	0 %	0 %	100 %

III. Decrease in apical diameter: Figure 4

➤ Effect of type of intracanal medication:

Statistical analysis showed that there was no statistically significant difference between all groups through the whole follow up period ($P > 0.05$) Table 4. Effect of time:

Statistically significant difference was found among all follow up periods Table 4.

IV. Periapical bone density: Figure 5

➤ Effect of type of intracanal medication:

Statistical analysis showed that there was no statistically

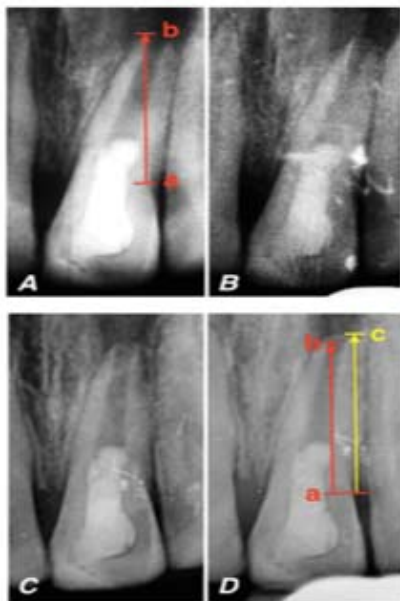

Figure 2: Representative case in TAP; A: preoperative radiograph, B: 6 month follow up radiograph, C: 12 month follow up radiograph, D: 18 month follow up radiograph. Note the increase in root length from (a-b) in the preoperative radiograph to (a-c) in the postoperative radiograph after 18 months of follow up.

Table 2: The mean percentage of increase in root length \pm SD of the four groups among the five evaluation periods.

	Group I (TAP)	Group II (DAP-1)	Group III (DAP-2)	Group IV (DAP-3)	Mean
3 months	4.8 \pm 3.1 % Ab	4.1 \pm 2.3 % Ab	3.6 \pm 2.1 % Ab	3.3 \pm 2.8 % Ab	3.9 \pm 2.6 %
6 months	6.4 \pm 2.4 % Abc	5.9 \pm 2.1 % Abc	6.4 \pm 3.3 % Abc	5.6 \pm 4.8 % Abc	6.1 \pm 3.2 %
9 months	9.7 \pm 2.5 % Acd	7.2 \pm 1.4 % Acd	8.5 \pm 4.2 % Acd	7.5 \pm 6 % Acd	8.2 \pm 3.9 %
12 months	11 \pm 2.6 % Ad	9.5 \pm 1.3 % Ad	12.8 \pm 7.2 % Ad	10.3 \pm 6.3 % Ad	10.9 \pm 5 %
18 months	15.9 \pm 5.7 % Ae	12.3 \pm 1 % Ae	20 \pm 12.7 % Ae	14.8 \pm 6.5 % Ae	15.7 \pm 7.9 %
Mean	9.5 \pm 5.2 %	7.8 \pm 3.3 %	10.3 \pm 8.7 %	8.3 \pm 6.6 %	

Significant at $p \leq 0.05$
 Different capital letters indicate significant difference between groups within the same follow-up period
 Similar small letter indicates insignificant difference between periods within the same group

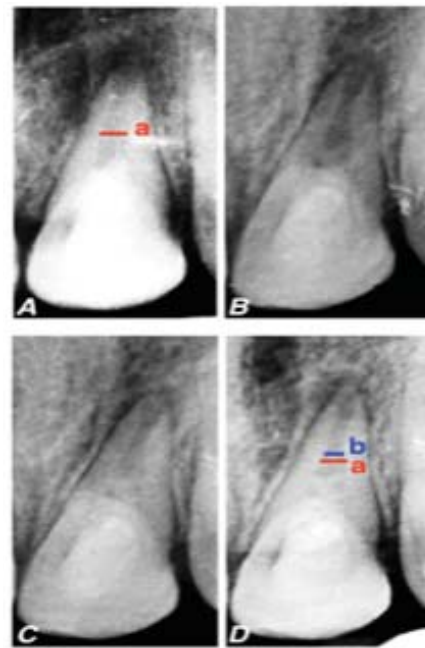


Figure 3: Representative case in group CP; A: preoperative radiograph, B: 6 month follow up radiograph, C: 12 month follow up radiograph, D: 18 month follow up radiograph. Note the increase in root thickness indicated by narrowing of pulp space from (a) in the preoperative radiograph to (b) in the postoperative radiograph after 18 months of follow up.

Table 3: The mean percentage of increase in root thickness \pm SD of the four groups among the five evaluation periods.

	Group I (TAP)	Group II (DAP-1)	Group III (DAP-2)	Group IV (DAP-3)	Mean
3 months	3 \pm 1.9 % Ab	2.7 \pm 1.9 % Ab	4.9 \pm 1.2 % Ab	2.9 \pm 1.5 % Ab	3.4 \pm 1.8 %
6 months	5.5 \pm 2.9 % Ac	5.8 \pm 2.5 % Ac	5.5 \pm 1.3 % Ac	6.1 \pm 2.6 % Ac	5.7 \pm 2.3 %
9 months	7 \pm 2.9 % Ac	6.9 \pm 2.5 % Ac	6.6 \pm 1.3 % Ac	7.7 \pm 2.8 % Ac	7.1 \pm 2.4 %
12 months	9.5 \pm 3.4 % Ad	9 \pm 2.4 % Ad	8.3 \pm 1.2 % Ad	10.3 \pm 3.7 % Ad	9.3 \pm 2.8 %
18 months	14.1 \pm 5.8 % Ae	12.9 \pm 3.9 % Ae	14.1 \pm 2 % Ae	15.4 \pm 3.6 % Ae	14.1 \pm 4 %
Mean	7.8 \pm 5.2 %	7.5 \pm 4.3 %	7.9 \pm 3.6 %	8.5 \pm 5.1 %	

Significant at $p \leq 0.05$
 Different capital letters indicate significant difference between groups within the same follow-up period
 Different small letters indicate significant difference between periods within the same group

significant difference between all groups through the whole follow up period ($P > 0.05$) Table 5.

➤ Effect of time:

Statistically significant difference was found among all follow up periods. Significant improvement in bone density was found after 9 months of follow up in each group Table 5.

Discussion

Triple antibiotic paste (TAP) has been found to have antimicrobial properties and to be biocompatible [19]. Ciprofloxacin inhibits DNA gyrase synthesis, metronidazole inhibits DNA synthesis, and minocycline inhibits protein synthesis of microbes [15]. Because case reports have shown

that minocycline causes visible crown discoloration [20,21]. In our study, Saline drops were added and mixed with the antibiotic combination until a creamy paste was achieved. This is consistent with most case reports, in which there was no attempt to deliberately deliver a specific concentration of the drugs. Instead, drugs were mixed until a certain physical consistency was achieved that was deemed suitable by clinicians [4].

Propolis was used as an intra-canal irrigant and has been found to be effective in reducing endotoxins and inhibiting *E. faecalis*, *Streptococcus aureus*, *Candida albicans* and *E. coli* [22]. Also, the co-adjuvant activity of propolis in antimicrobial therapy was confirmed [23]. In vitro experiments have shown

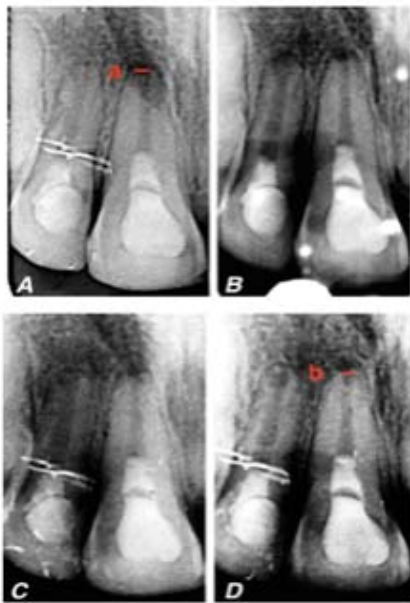

Figure 4: Representative case in group CM; A: preoperative radiograph, B: 6 month follow up radiograph, C: 12 month follow up radiograph, D: 18 month follow up radiograph. Note the decrease in apical diameter from (a) in the preoperative radiograph to (b) in the postoperative radiograph after 18 months of follow up.

Table 4: The mean percentage of decrease in apical diameter ± SD of the four groups among the five evaluation periods.

	Group I (TAP)	Group II (DAP-1)	Group III (DAP-2)	Group IV (DAP-3)	Mean
3 months	7.1±5.4 % Ab	5.1±0.5 % Ab	10.8±6.8 % Ab	7.1±2.6 % Ab	7.5±4.8 %
6 months	15.9±2.6 % Ac	14.6±1.1 % Ac	22.3±11.3 % Ac	12.6±4.1 % Ac	16.3±7 %
9 months	23.3±0.3 % Ad	23.2±0.3 % Ad	26.1±10.6 % Ad	19.9±6.3 % Ad	23.1±6.3 %
12 months	32.3±7.6 % Ae	30.9±1.2 % Ae	32.1±8.9 % Ae	30.8±11.7 % Ae	31.5±8 %
18 months	46.3±12 % Af	50.1±0.3 % Af	48.7±10.2 % Af	54.5±6.9 % Af	49.9±8.8 %
Mean	25±15.2 %	24.8±15.5 %	28±15.7 %	25±18.2 %	

Significant at $p \leq 0.05$
 Different capital letters indicate significant difference between groups within the same follow-up period
 Different small letters indicate significant difference between periods within the same group

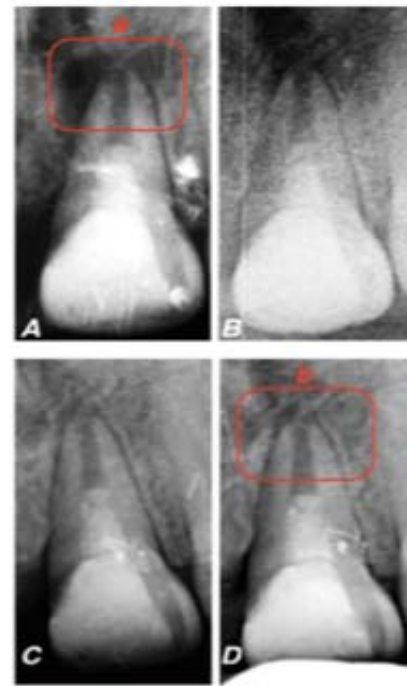

Figure 5: Representative case in group PM; A: preoperative radiograph, B: 6 month follow up radiograph, C: 12 month follow up radiograph, D: 18 month follow up radiograph. Note the increase in periapical bone density from (a) in the preoperative radiograph to (b) in the postoperative radiograph after 18 months of follow up.

Table 5: The mean percentage of increase in periapical bone density ± SD of the four groups among the five evaluation periods.

	Group I (TAP)	Group II (DAP-1)	Group III (DAP-2)	Group IV (DAP-3)	Mean
3 months	6.1±1.5 % Ab	6±1.2 % Ab	6.2±1.2 % Ab	5.8±1.4 % Ab	6±1.3 %
6 months	9.3±1.5 % Ac	9.6±1.5 % Ac	9.5±1.7 % Ac	9.7±2.1 % Ac	9.5±1.7 %
9 months	10.4±2.4 % Ad	11.1±2.1 % Ad	10.8±2.5 % Ad	11.2±2.3 % Ad	10.9±2.3 %
12 months	12.7±1.8 % Ae	13±2 % Ae	12.8±2.2 % Ae	13.3±2.5 % Ae	12.9±2.1 %
18 months	17.8±1.9 % Af	18.6±1.6 % Af	18.6±1.3 % Af	18.1±1.7 % Af	18.3±1.6 %
Mean	11.3±4.3 %	11.7±4.5 %	11.6±4.5 %	11.6±4.5 %	

Significant at $p \leq 0.05$
 Different capital letters indicate significant difference between groups within the same follow-up period
 Different small letters indicate significant difference between periods within the same group

that propolis presents a high level of artemillin-C, inhibiting the cyclo-oxygenase pathway and eicosanoid synthesis [24]. In addition, studies have observed that propolis promotes regeneration of dental pulp [25].

Immature permanent teeth with necrotic pulp and an apical opening that measures 1 mm or larger were selected because they are considered suitable candidates for treatment [26,27]. Mechanical instrumentation is contraindicated, not only to avoid further weakening the thin root canal walls, but also to protect the vitality of stem cells of apical tissues [2]. However, Lin et al. 2014 published a failed clinical case of regenerative endodontic therapy due to the bacterial biofilms that remained firmly attached to the apical canal walls because

of the lack of mechanical debridement [28]. Therefore, there is a trend for even slightly mechanical instrumentation in recent publications [4,29], which was made in our study.

Our clinical observations are in agreement with Paryani and Kim [30]. Our clinical results are also in full agreement with a retrospective study, which demonstrated 100% survival rate of teeth after regenerative treatment [31]. In a retrospective study of 30 cases, followed for up to 1 year, only two cases had complications, which were restricted to discomfort or discoloration [17], which is consistent with our study.

The bone density results in our study showed an increase in the radio-opacity of previously rarefacted areas. This indicates a favorable healing response to the treatment. In the majority of our cases, improvement or resolution of the apical lesion was evident in approximately 6 months. Root elongation and apical closure, with thickening of the root canal walls, was evident after 12-16 months postoperatively.

Our findings concerning the increase in length and thickness were in agreement with many authors [5,19,26,32]. Our findings were also in agreement with other authors [33,34], who reported an increase in length and thickness without quantitative measurements. The results of our study are in disagreement with Lin et al., [28], where the failure was attributed to inadequate root canal disinfection without mechanical removal of biofilm and bacteria in dentinal tubules.

All of groups, except group 3 (DAP-2, Ciprofloxacin+Metronidazole), have shown cervical discoloration, which can be due to using minocycline or propolis in the intracanal medicament [35,36]. There are reports that white MTA may also discolor the tooth structure [7,37,38].

Conclusions

All tested intracanal medicaments paved the way for successful pulp revascularization process in immature permanent anterior teeth, which was evident by continued root growth and resolution of periapical radiolucency. Therefore, the null hypothesis was accepted.

Recommendations

Follow up visits should be scheduled every 6 months, rather than 3 months, to observe root changes after pulp revascularization procedure. Longer follow up period (>18 months) is needed for monitoring of complete root maturogenesis.

Acknowledgments

The authors deny any conflict of interest related to this study.

References

- Law A (2013) Considerations for Regeneration Procedures. *J Endod* 39:44-56. [Link: https://bit.ly/2YALJQJ](https://bit.ly/2YALJQJ)
- Wigler R, Kaufman AY, Lin S, Steinbock N, Hazan-Molina H, et al. (2013) Revascularization: A Treatment for Permanent Teeth with Necrotic Pulp and Incomplete Root Development. *J Endod* 39: 319-326. [Link: https://bit.ly/2yuy1x](https://bit.ly/2yuy1x)
- Hoshino E, Kurihara-Ando N, Sato I, Uematsu H, Sato M, et al. (1996) In Vitro Antibacterial Susceptibility of Bacteria Taken from Infected Root Dentine to a Mixture of Ciprofloxacin, Metronidazole and Minocycline. *Int Endod J* 29:125-130. [Link: https://bit.ly/2LT9Zrj](https://bit.ly/2LT9Zrj)
- Nagy M, Tawfik H, Hashem A, Abu-Seida A (2014) Regenerative Potential of Immature Permanent Teeth with Necrotic Pulps after Different Regenerative Protocols. *J Endod* 40: 192-198. [Link: https://bit.ly/2TOLWHD](https://bit.ly/2TOLWHD)
- Tawfik H, Abu-Seida A, Hashem A, Nagy M (2013) Regenerative Potential following Revascularization of Immature Permanent Teeth with Necrotic Pulps. *Int Endod J* 46: 910-922. [Link: https://bit.ly/2ovU59e](https://bit.ly/2ovU59e)
- Ruparel N, Teixeira F, Ferraz C, Diogenes A (2012) Direct Effect of Intracanal Medicaments on Survival of Stem Cells of the Apical Papilla. *J Endod* 38: 1372-1375. [Link: https://bit.ly/338epA7](https://bit.ly/338epA7)
- Nosrat A, Homayounfar N, Oloomi K (2012) Drawbacks and Unfavorable Outcomes of Regenerative Endodontic Treatments of Necrotic Immature Teeth: A Literature Review and Report of a Case. *J Endod* 38: 1428-1434. [Link: https://bit.ly/2OBGdtt](https://bit.ly/2OBGdtt)
- Berkhoff J, Chen P, Teixeira F, Diogenes A (2014) Evaluation of Triple Antibiotic Paste Removal by Different Irrigation Procedures. *J Endod* 40: 1172-1177. [Link: https://bit.ly/2SYeBx9](https://bit.ly/2SYeBx9)
- Al-Shaher A, Wallace J, Agarwal S, Bretz W, Baugh D, et al. (2004) Effect of Propolis on Human Fibroblasts from the Pulp and Periodontal Ligament. *J Endod* 30: 359-61. [Link: https://bit.ly/2SZAaNG](https://bit.ly/2SZAaNG)
- Sabrah A, Yassen G, Gregory R. (2013) Effectiveness of Antibiotic Medicaments against Biofilm Formation of *Enterococcus Faecalis* and *Porphyromonas Gingivalis*. *J Endod* 39: 1385-1389. [Link: https://bit.ly/2MAfD1g](https://bit.ly/2MAfD1g)
- Sosnowski, Z. (1983) Method for Extracting Propolis and Water Soluble Dry Propolis Powder. United States Patent [Link: https://bit.ly/2LWo4V8](https://bit.ly/2LWo4V8)
- Savickas A, Ramanauskienė K, Pukalskas A, Giedrė Kasparavičienė, et al. (2010) The Influence of Solvent on The Quantity and Antioxidant Activity of Ethanolic Extracts of Lithuanian Propolis. *Chemija* 21: 118-122. [Link: https://bit.ly/2MAphkq](https://bit.ly/2MAphkq)
- Lenzi R, Trope M (2012) Revitalization Procedures in Two Traumatized Incisors with Different Biological Outcomes. *J Endod* 38: 411-414. [Link: https://bit.ly/2SYgU3h](https://bit.ly/2SYgU3h)
- Nagata J, Soares A, Souza-Filho F, Zaia AA1, Ferraz CC, et al. (2014) Microbial Evaluation of Traumatized Teeth Treated with Triple Antibiotic Paste or Calcium Hydroxide with 2% Chlorhexidine Gel in Pulp Revascularization. *J Endod* 40: 778-783. [Link: https://bit.ly/2SZCy78](https://bit.ly/2SZCy78)
- Rodriguez-Benitez S, Stambolsky C, Gutierrez-Perez J, Torres-Lagares D, Segura-Egea J (2015) Pulp Revascularization of Immature Dog Teeth with Apical Periodontitis Using Triantibiotic Paste and Platelet-rich Plasma: A Radiographic Study. *J Endod* 41: 1299-1304. [Link: https://bit.ly/2KnEnHj](https://bit.ly/2KnEnHj)
- Lovelace T, Henry M, Hargreaves K, Diogenes A (2011) Evaluation of the Delivery of Mesenchymal Stem Cells into the Root Canal Space of Necrotic Immature Teeth after Clinical Regenerative Endodontic Procedure. *J Endod* 37: 133-138. [Link: https://bit.ly/2Yzjb61](https://bit.ly/2Yzjb61)
- Garcia-Godoy F, Murray PE. (2012) Recommendations for Using Regenerative Endodontic Procedures in Permanent Immature Traumatized Teeth. *Dent Traumatol* 28: 33-41. [Link: https://bit.ly/2KjxDKn](https://bit.ly/2KjxDKn)
- Bose R, Nummikoski P, Hargreaves K (2009) A Retrospective Evaluation of Radiographic Outcomes in Immature Teeth with Necrotic Root Canal Systems Treated with Regenerative Endodontic Procedures. *J Endod* 35: 1343-1349. [Link: https://bit.ly/2K9McBs](https://bit.ly/2K9McBs)

19. Gomes-Filho J, Duarte P, de Oliveira C, Watanabe S, Lodi CS, et al. (2012) Tissue Reaction to a Triantibiotic Paste Used for Endodontic Tissue Self-Regeneration of Nonvital Immature Permanent Teeth. *J Endod* 38: 91–94. [Link: https://bit.ly/2ZqwDKQ](https://bit.ly/2ZqwDKQ)
20. Jeeruphan T, Jantararat J, Yanpiset K, Suwannapan L, Khewsawai P, et al. (2012) Mahidol Study 1: Comparison of Radiographic and Survival Outcomes of Immature Teeth Treated with either Regenerative Endodontic or Apexification Methods - A Retrospective Study. *J Endod* 38: 1330-1336. [Link: https://bit.ly/2KkqcT9](https://bit.ly/2KkqcT9)
21. Kim J, Kim Y, Shin S, Park JW, Jung IY et al. (2010) Tooth Discoloration of Immature Permanent Incisor Associated with Triple Antibiotic Therapy: A Case Report. *J Endod* 36: 1086–1091. [Link: https://bit.ly/2T2cYhU](https://bit.ly/2T2cYhU)
22. Arslan S, Ozbilge H, Kaya E, Ozgur E. (2011) In Vitro Antimicrobial Activity of Propolis, Biopure MTAD, Sodium Hypochlorite, and Chlorhexidine on *Enterococcus Faecalis* and *Candida Albicans*. *Saudi Med J* 32: 479-483. [Link: https://bit.ly/2YwF17J](https://bit.ly/2YwF17J)
23. Victorino F, Franco S, Svidzinski T, Mário Julio Avila-Campos, Roberto Kenji Nakamura Cuman, et al. (2007) Pharmacological Evaluation of Propolis Solutions for Endodontic Use. *Pharmaceutical Biology* 45: 721–727. [Link: https://bit.ly/2ZpxtaA](https://bit.ly/2ZpxtaA)
24. Pileggi R, Antony K, Johnson K, Zuo J, Holliday L (2009) Propolis Inhibits Osteoclast Maturation. *Dental Traumatology* 25: 584–588. [Link: https://bit.ly/2KdqPPM](https://bit.ly/2KdqPPM)
25. Neiva K, Catalfamo D, Holliday S, Wallet S, Pileggi R. (2014) Propolis Decreases Lipopolysaccharide-Induced Inflammatory Mediators in Pulp Cells and Osteoclasts. *Dental Traumatology* 30: 362–367. [Link: https://bit.ly/2KjF9oz](https://bit.ly/2KjF9oz)
26. Estefan B, El-Batouty K, Nagy M, Diogenes A. (2016) Influence of Age and Apical Diameter on the Success of Endodontic Regeneration Procedures. *J Endod* 42: 1620–1625. [Link: https://bit.ly/332CUPb](https://bit.ly/332CUPb)
27. Kling M, Cvek M, Mejare I (1986) Rate and Predictability of Pulp Revascularization in Therapeutically Reimplanted Permanent Incisors. *Endod Dent Traumatol* 2: 83–89. [Link: https://bit.ly/2yvw1wt](https://bit.ly/2yvw1wt)
28. Lin L, Shimizu E, Gibbs J, Loghin S, Ricucci D, et al (2014). Histologic and Histobacteriologic Observations of Failed Revascularization/Revitalization Therapy: A Case Report. *J Endod* 40: 291–295. [Link: https://bit.ly/2YBrkuS](https://bit.ly/2YBrkuS)
29. Alobaid A, Cortes L, Jeffery Lo, Nguyen TT, Albert J, et al. (2014) Radiographic and Clinical Outcomes of the Treatment of Immature Permanent Teeth by Revascularization or Apexification: A Pilot Retrospective Cohort Study. *J Endod* 40: 1063–1070. [Link: https://bit.ly/2yxYlQs](https://bit.ly/2yxYlQs)
30. Paryani K, Kim S (2013) Regenerative Endodontic Treatment of Permanent Teeth after Completion of Root Development: A Report of 2 Cases. *J Endod* 39: 929–934. [Link: https://bit.ly/2YB44Jr](https://bit.ly/2YB44Jr)
31. Cehreli ZC, Ishitire B, Sara S, Erbas G (2011) Regenerative Endodontic Treatment (Revascularization) of Immature Necrotic Molars Medicated with Calcium Hydroxide: A Case Series. *J Endod* 37: 1327-1330. [Link: https://bit.ly/332Fc0t](https://bit.ly/332Fc0t)
32. Nosrat A, Seifi A, Asgary S (2011) Regenerative Endodontic Treatment (Revascularization) for Necrotic Immature Permanent Molars: A Review and Report of Two Cases with New Biomaterial. *J Endod* 37: 562-567. [Link: https://bit.ly/31eeMaC](https://bit.ly/31eeMaC)
33. Banchs F, Trope M (2004) Revascularization of Immature Permanent Teeth with Apical Periodontitis: New Treatment Protocol. *J Endod* 30: 196-200. [Link: https://bit.ly/2LY87gQ](https://bit.ly/2LY87gQ)
34. Iwaya S, Ikawa M, Kubota M (2011) Revascularization of an Immature Permanent Tooth with Periradicular Abscess after Luxation. *Dent Traumatol* 37: 55-58. [Link: https://bit.ly/31d26k9](https://bit.ly/31d26k9)
35. Nagata J, Gomes B, Lima T, Murakami LS, de Faria DE (2014) et al. Traumatized Immature Teeth Treated with 2 Protocols of Pulp Revascularization. *J Endod* 40: 606–612. [Link: https://bit.ly/2MxwdDq](https://bit.ly/2MxwdDq)
36. Akcay M, Arslan H, Yasa B, Kavrik F, Yasa E, et al. (2014) Spectrophotometric Analysis of Crown Discoloration Induced by Various Antibiotic Pastes Used in Revascularization. *J Endod* 40: 845–848. [Link: https://bit.ly/338crzo](https://bit.ly/338crzo)
37. Miller E, Lee J, Tawil P, Teixeira FB, Vann WF Jr, et al. (2012) Emerging Therapies for the Management of Traumatized Immature Permanent Incisors. *Pediatr Dent* 34: 66–69. [Link: https://bit.ly/2GHaQr4](https://bit.ly/2GHaQr4)
38. Lenherr P, Allgayer N, Weiger R, Filippi A, Attin T, et al. (2012) Tooth Discoloration Induced by Endodontic Materials: A Laboratory Study. *Int Endod J* 45: 942–949. [Link: https://bit.ly/2LW6eTs](https://bit.ly/2LW6eTs)

Discover a bigger Impact and Visibility of your article publication with Peertechz Publications

Highlights

- ❖ Signatory publisher of ORCID
- ❖ Signatory Publisher of DORA (San Francisco Declaration on Research Assessment)
- ❖ Articles archived in worlds' renowned service providers such as Portico, CNKI, AGRIS, TDNet, Base (Bielefeld University Library), CrossRef, Scilit, J-Gate etc.
- ❖ Journals indexed in ICMJE, SHERPA/ROMEO, Google Scholar etc.
- ❖ OAI-PMH (Open Archives Initiative Protocol for Metadata Harvesting)
- ❖ Dedicated Editorial Board for every journal
- ❖ Accurate and rapid peer-review process
- ❖ Increased citations of published articles through promotions
- ❖ Reduced timeline for article publication

Submit your articles and experience a new surge in publication services (<https://www.peertechz.com/submission>).

Peertechz journals wishes everlasting success in your every endeavours.

Copyright: © 2019 Abdelrahman Mohamed Yehia TY, et al. This is an open-access article distributed under the terms of the Creative Commons Attribution License, which permits unrestricted use, distribution, and reproduction in any medium, provided the original author and source are credited.

Citation: Abdelrahman Mohamed Yehia TY, El-Ashry S, El-Batoty K, El-Hady S (2019) Efficiency of Triple Antibiotic Mixture and Propolis as Intracanal Medication in Revascularization process in immature apex: A clinical study. *Glob J Medical Clin Case Rep* 6(2): 019-025. DOI: <http://doi.org/10.17352/2455-5282.000073>