

## Case Report

# Chlorine inhalation injury with acute respiratory distress syndrome treated by extra-corporeal membrane oxygenation system

Te-Fu Chen<sup>1,2</sup>, Chih-Hsien Wang<sup>3</sup>, Gonzalez Lain Hermes<sup>2</sup> and Wen-Je Ko<sup>3\*</sup>

<sup>1</sup>Division of Neurosurgery, Department of Surgery, National Taiwan University Hospital, National Taiwan University College of Medicine, Taipei, Taiwan

<sup>2</sup>Non-Invasive Cancer Therapy Research Institute Taiwan, Taipei, Taiwan

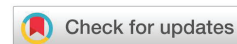<sup>3</sup>Department of Traumatology, National Taiwan University Hospital, National Taiwan University College of Medicine, Taipei, Taiwan

**Received:** 06 April, 2020  
**Accepted:** 10 April, 2020  
**Published:** 11 April, 2020

**\*Corresponding author:** Wen-Je Ko, MD, PhD, National Taiwan University Hospital, Department of Traumatology, National Taiwan University College of Medicine, Taipei, Taiwan, Tel: +886-2-23123456; Fax:+886-2-25171193; E-mail: [kowj@ntu.edu.tw](mailto:kowj@ntu.edu.tw)

**Keywords:** Chlorine; Acute inhalation injury; Acute respiratory distress syndrome; ARDS; Extracorporeal membranous oxygenation; ECMO; Respiratory failure

<https://www.peertechz.com>



## Abstract

Chlorine inhalation related Acute Respiratory Distress Syndrome (ARDS) is rare in clinical practice. Although full recovery from chlorine inhalation injuries remains the most likely outcome, it is true that permanent disability of lung function or even a fatal outcome are possible in severe cases. Reviewing the literature, there are some reports wherein severely injured cases have a mortal outcome. We report a case of high-dose chlorine inhalation injury which induced ARDS and severe acidosis with refractory shock status 4 hours after the initial insult. A vein to artery Extra-Corporeal Membrane Oxygenation (ECMO) system was applied for the ARDS and systemic steroid therapy was also administered. The patient had a good recovery of the pulmonary oxygenation after 70 hours of ECMO support and intubation and ventilation support for five days. He was then transferred to the ward after a one-week stay in the intensive care unit. Oral steroids were gradually tapered over 4 weeks. The follow-up pulmonary function test, performed 6 weeks after the injury, revealed fair recovery without remarkable sequelae while the high resolution pulmonary computed tomography showed bilateral pulmonary fibrosis. To the best of our knowledge, this is the first case report wherein an ECMO system has succeeded in salvaging a patient who suffered from chlorine inhalation injury complicated with ARDS and refractory shock. It is noteworthy that the ECMO system may be deemed beneficial for this group of patients so long as there is no clinical contraindication for the use of such a therapeutic strategy.

## Background

Chlorine inhalation related Acute Respiratory Distress Syndrome (ARDS) is rare in clinical practice. It is true that permanent disability of lung function or even a fatal outcome are possible in severe cases. We present an aggressive treatment strategy for this group of patients for better clinical outcome in this study.

## Case presentation

A 57-year old man who had been hitherto working in

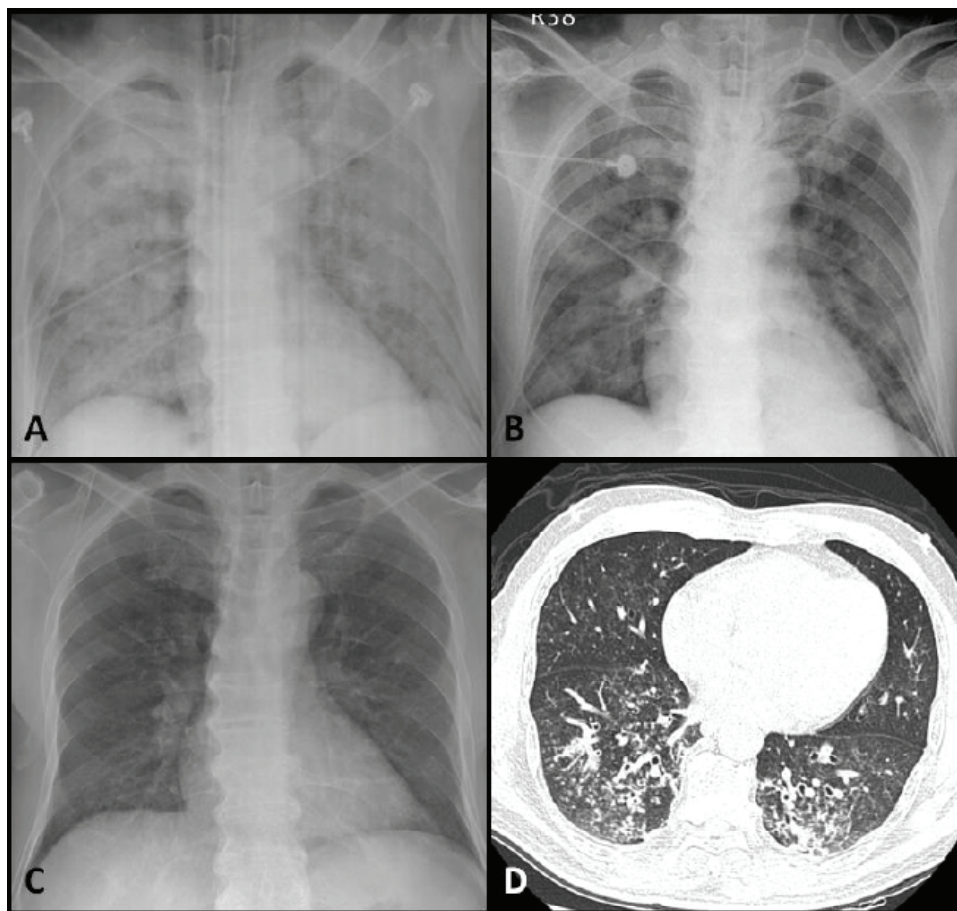
the electric industry for many years was presented in the emergency department of our institution. Throughout the same day, he had been working in a non-ventilated room without mask protection while pure chlorine leaked from a pipe occurred for 3 hours. He experienced headache, dyspnea, palpitations and chest tightness 4 hours later and was sent to our hospital with an oxygen mask, anxious consciousness, and obvious tachypnea.

Upon arrival to the emergency room, the oxygen saturation of the patient was 91% using a non-rebreathing mask. Bilateral diffuse wheezing, rales and respiratory distress were noticed on

physical examination. Consequently, he was intubated. A chest x-ray was ordered and it showed diffuse increased haziness over bilateral pulmonary parenchyma (Figure 1-A). Complete blood count and biochemistry profiles including liver function test, electrolytes, renal function test and coagulation profile were within normal limits. Furthermore, the serum and urine toxicology ascertained no remarkable findings. Arterial blood gas revealed a pH of 7.35,  $pCO_2$  of 42.8 mmHg and  $pO_2$  of 22.7 mmHg, under 100%  $FiO_2$  supplementation via endotracheal tube and 20 mmHg Positive End-Expiratory Pressure (PEEP). The pulse oximetry showed a saturation of 70%. Subsequently, refractory shock status developed one hour later despite the fact that we kept adequate intravascular volume, acid-base balance, dosage of inotropics and bronchodilators.

Given such an ominous clinical status, we then performed a venoarterial extra-corporeal membranous oxygenation (V-A ECMO) on the right femoral artery and vein of this patient. The vital signs became stable with a blood pressure of 109/62 mmHg, heart rate of 105 beats per minute with sinus tachycardia and body temperature of 37.1 degrees Celsius. The arterial blood gas at that time revealed a pH of 7.28,  $pCO_2$  of 43.3 mmHg and  $pO_2$  of 153.8 mmHg. We set the ventilator in lung protection mode and the blood flow assisted from the ECMO was 1.9-2.1 L/min. The other therapeutic maneuvers at the UCI were:

prophylactic antibiotics, proton pump inhibitors, sedatives, bronchodilators, intravenous corticosteroids and enteral tube nutrition. Fiberoptic bronchoscopy showed hyperaemic mucosa without airway abnormality. For a period of 50 hours, stationary arterial  $pO_2$  values higher than 90 mmHg under the V-A ECMO system support were registered. No further worsening of airspace disease on the chest x-ray developed during the next two days. Under stable vital signs and stationary arterial  $pO_2$  level, we weaned off the V-A ECMO successfully after 70 hours of support. The patient kept receiving bronchodilator therapy and inhaled steroids were given following the weaning off of the ECMO. The arterial  $pO_2$  value improved day by day from 77 to 108 mmHg and the patient was extubated on the 6<sup>th</sup> day after the initial insult. Then, he was transferred to the general ward where he was given  $O_2$  through nasal cannula so as to alleviate the mild dyspnea the patient was still complaining of. A chest High-Resolution Computed Tomography (chest HRCT) on day 9 showed mild bronchial wall thickening at bilateral lower lung fields and ground glass opacities throughout the lungs (Figure 1-D). The patient received oral steroids (prednisone 1 mg/kg since day 12 and he was discharged after 15 days of hospitalization. At the time of discharge, he could perform daily activities without assistance. Some days after, the follow-up pulmonary function test (Spirometry by CHESTAC-8800) disclosed normal standard spirometry data.



**Figure 1:** Initial CXR after endotracheal tube intubation showed bilateral diffusely haziness of lung. B: CXR on day 3 after intubation; the ECMO was removed C: CXR on week 4 showed normalized lung markings. D: The CT revealed mild bronchial wall thickening at bilateral lower lung fields and ground glass opacities throughout the lungs. (CXR: chest X-ray; ECMO: Extra-corporeal Membrane Oxygenation)



## Discussion

Chlorine is one of the most pervasive toxic inhalants, although it was discovered in 1772. It is a yellow-green gas at room temperature with detectable odor. However, with prolonged exposure to chlorine, the ability to detect it tends to vanish. Chlorine is of widespread use in both households and industrial fields, and it has even been used as a weapon during previous wars [1]. Currently, human exposure to chlorine inhalation potentially occurs in a variety of settings such as a chemical warfare agent, domestic exposure, industrial exposure, swimming pool exposure, and as a result of accidents. The initial symptoms include dyspnea, tachypnea, chest tightness, cyanosis, etc. Treatment of chlorine exposure is essentially symptomatic and only rare cases developed Acute Respiratory Distress Syndrome (ARDS). The majority of chlorine related inhalation injuries has only minor symptoms like mucosal and ocular irritation, although in the event of an exposure to higher concentrations of chlorine complications such as pneumonitis, pulmonary edema, respiratory failure and death may occur [2]. Most of the patients with acute chlorine exposure recovered without remarkable sequelae and only supportive therapy was deemed mandatory. The mean hospital stay length was less than 4 days. The long term sequelae had been described before and they include the development of occupational asthma(3), reactive airways dysfunction syndrome [4,5], and increased airway responsiveness [6].

The main destructive features of chlorine inhalation are direct mucosal injury and the release of free radicals which consequently give rise to an inflammation process which produces Acute Lung Injury (ALI) or ARDS. Hypoxia is the hallmark of  $Cl_2$  inhalation injuries [7]. The specific cause of hypoxia may be both V/Q mismatch and shunt formation [8].

According to the thoroughly reviewed literature regarding chlorine inhalation injury, ARDS is a rare presentation and mechanical ventilation is seldom used. The outcomes have been reported to be generally good with a low mortality rate, which was only 0.58% in cases of accidental chlorine exposure according to Evans' review [9]. On the other hand, should the patient develop ALI or ARDS, the administration of mechanical ventilation for a brief period of time, could be a life-saving measure. The cases that required mechanical ventilation are summarized in Table 1 [10-16]. Up to 39 cases that needed ventilation support after chlorine inhalation can be found in the reported cases. Among them, 15 cases had a mortal outcome, which yields a mortality rate of 38.5%. The majority of deaths occurred within the first 3 days. The length of hospital stay ranged from 6 to 28.5 days and the complications included asthma and pneumothorax.

The ventilator settings for ARDS typically include: high PEEP, high frequency, permissive hypercapnia, and lower tidal volume ventilation [17]. The usage of intravenous corticosteroids and inhalation of beta-agonists had been widely discussed before for chlorine-related inhalation injury [14,18]. The goal of systemic corticosteroids administration in chlorine-related ARDS patients is to minimize the fibroproliferative phase of ARDS in lieu of the acute inflammatory phase [19]. However, should a higher concentration of chlorine exposure occur along with its consequent ARDS and unstable hemodynamics, the course in the first 72 hours would be miserable, in spite of thoughtful therapeutic management. According to a study with sheep, individuals with ARDS and shock will have stabilized vital signs 3 days after the chlorine exposure [20]. Therefore, it is important to focus on optimal management during this first critical period time which is mainly the first 72 hours after the insult. Under clinically feasibility, the veno-arterial

**Table 1:** Summary of ARDS in prior case reports and case studies involving chlorine exposure.

Author, Y	Mode of Exposure	Individuals Exposed (n)	ARDS needs Mechanical Ventilation (n)	Length of stay (day)	Complication	Mortality
D. Van Sickle et al, 2009	train derailment Chlorine gas	79	29	6	N/A	9
Hjorts et al, 1988	Military training ZnCl <sub>2</sub>	5	2	28.5	N/A	2
Martines & Long, 1995	Swimming pool Chlorination	2	2	11	N/A	1
Mapp et al, 2000	Mixing of cleaning detergents	1	1	21	asthma	0
Pettilä et al, 2000	Smoke inhalation ZnCl <sub>2</sub>	3	3	19	emphysema bullae	2
Rajesh et al, 2008	Swimming pool Cl <sub>2</sub> inhalation	1	1	28	pneumothorax	0
Gil et al, 2008	Fire training exercise ZnCl <sub>2</sub>	1	1	9	N/A	1



ECMO system assists in overcoming this critical acute stage of high concentration chlorine inhalation injury and should be hence chosen as a useful tool so as to salvage the patient. It is commonly accepted that V-V access is the favored cannulation method for treating patients with pure respiratory failure. Nonetheless, our patient had refractory shock under vasopressors infusion and such a clinical situation compelled us to make the decision of establishing V-A cannulation.

Some complications in treating patients with ARDS have been reported, which mainly were mainly owed to the mechanical effects that cause a decreased venous return, hemodynamic compromise, ventilator-Associated Lung Injury (VALI) and upregulation of the inflammatory response in the injured and overdistended lung [21]. Ventilator associated barotrauma in chlorine inhalation injury patients with ARDS has been reported [14] and the ECMO system for this group of patients will offer benefits such as alleviating the barotraumas, giving time to the lung for repair and shortening the length of the hospital stay. But this statement is based only on clinical observation. The effects on acute pulmonary inflammation, long-term sequelae, and superimposed infection still need to be explored.

In spite of the patient's uneventful clinical course and satisfactory outcome, the potential complications from the ECMO itself should not be underestimated, namely: excessive bleeding from wounds, coagulopathy, hemolysis, thrombus formation in arteries and/or veins, gangrenous change in the extremities, and bacteremia. Leaving the clinical complications aside, cost-effectiveness is another issue to be borne in mind as well.

## Conclusion

Chlorine inhalation injury accompanied with ARDS and necessity of ventilator support is a rarely seen clinical situation. A fatal outcome or concomitant refractory shock and hypoxemia under conventional therapeutic intervention are even rarer occurrences. In order to offer the patients a better chance to overcome the acute stage of chlorine inhalation injury, provided an ECMO system is clinically available, its application may be a life-saving and worthy intervention.

## Consent

Written informed consent was obtained from the patient for publication of this Case report and any accompanying images. A copy of the written consent is available for review by the Editor-in-Chief of this journal.

## Competing interests

In the past five years we have never received reimbursements, fees, funding, or salary from an organization that may in any way gain or lose financially from the publication of this manuscript, either now nor in the future. There are no non-financial competing interests (political, personal, religious, ideological, academic, intellectual, commercial or any other) to declare in relation to this manuscript.

## Authors' contributions

Te-Fu Chen carried out the patient primary care, medical records, reference collection and drafted the manuscript. Chih-Hsien Wang and Gonzalez Lain Hermes conceived of the study, and participated in its design and coordination and helped to draft the manuscript. Wen-Je Ko are corresponded of this manuscript. All authors read and approved the final manuscript.

## Acknowledgement

We would like to give special and sincerely thank to the nursing system and the ECMO team in our institute - National Taiwan University Hospital, for their perfect works and passions to rescue patients.

## References

- Balmes J (1992) Acute pulmonary injury from hazardous materials. Hazardous materials toxicology: clinical principles of environmental health Baltimore: The Williams and Wilkins Co 425-432.
- Winder C (2001) The Toxicology of Chlorine. *Environ Res* 85: 105-114. [Link: https://bit.ly/34wQRWv](https://bit.ly/34wQRWv)
- Thickett KM, McCoach JS, Gerber JM, Sadhra S, Burge PS (2002) Occupational asthma caused by chloramines in indoor swimming-pool air. *Eur Respir J* 19: 827-832. [Link: https://bit.ly/2JYGzoN](https://bit.ly/2JYGzoN)
- D'Alessandro A, Kuschner W, Wong H, Boushey HA, Blanc PD (1996) Exaggerated responses to chlorine inhalation among persons with nonspecific airway hyperreactivity. *Chest* 109: 331-337. [Link: https://bit.ly/3e6gGRE](https://bit.ly/3e6gGRE)
- Gorguner M, Aslan S, Inandi T, Cakir Z (2004) Reactive airways dysfunction syndrome in housewives due to a bleach-hydrochloric acid mixture. *Inhal Toxicol* 16: 87-91. [Link: https://bit.ly/2JT3SAp](https://bit.ly/2JT3SAp)
- Schonhofer B, Voshaar T, Kohler D (1996) Long-term lung sequelae following accidental chlorine gas exposure. *Respiration* 63: 155-159. [Link: https://bit.ly/3b5hYKQ](https://bit.ly/3b5hYKQ)
- Das R, Blanc PD (1993) Chlorine Gas Exposure and the Lung: A Review. *Toxicol Ind Health* 9: 439-455. [Link: https://bit.ly/2UZz0tb](https://bit.ly/2UZz0tb)
- Shimazu T, Yukioka T, Ikeuchi H, Mason AD, Wagner PD et al. (1996) Ventilation-perfusion alterations after smoke inhalation injury in an ovine model. *J Appl Physiol* (Bethesda, Md : 1985) 81: 2250-2259. [Link: https://bit.ly/2XqJLBq](https://bit.ly/2XqJLBq)
- Evans RB (2005) Chlorine: state of the art. *Lung* 183: 151-167. [Link: https://bit.ly/34pX3Qe](https://bit.ly/34pX3Qe)
- Hjortso E, Ovist J, Bud MI, Thomsen JL, Andersen JB, et al. (1988) ARDS after accidental inhalation of zinc chloride smoke. *Intensive Care Med* 14: 17-24. [Link: https://bit.ly/2XslUAo](https://bit.ly/2XslUAo)
- Martinez TT, Long C (1995) Explosion risk from swimming pool chlorinators and review of chlorine toxicity. *J Toxicol Clin Toxicol* 33: 349-354. [Link: https://bit.ly/2Xrm7EX](https://bit.ly/2Xrm7EX)
- Mapp CE, Pozzato V, Pavoni V, Gritti G (2000) Severe asthma and ARDS triggered by acute short-term exposure to commonly used cleaning detergents. *Eur Respir J* 16: 570-572. [Link: https://bit.ly/2XolwUx](https://bit.ly/2XolwUx)
- Pettila V, Takkunen O, Tukiainen P (2000) Zinc chloride smoke inhalation: a rare cause of severe acute respiratory distress syndrome. *Intensive Care Med* 26: 215-217. [Link: https://bit.ly/34pWkhW](https://bit.ly/34pWkhW)



14. Babu RV, Cardenas V, Sharma G (2008) Acute respiratory distress syndrome from chlorine inhalation during a swimming pool accident: a case report and review of the literature. *J Intensive Care Med* 23: 275-280. [Link: https://bit.ly/39ZsFNL](https://bit.ly/39ZsFNL)
15. Gil F, Pla A, Hernandez AF, Mercado JM, Mendez F (2008) A fatal case following exposure to zinc chloride and hexachloroethane from a smoke bomb in a fire simulation at a school. *Clinical toxicology (Phila)* 46: 563-565. [Link: https://bit.ly/2VdrJje](https://bit.ly/2VdrJje)
16. Van Sickle D, Wenck MA, Belflower A, Drociuk D, Ferdinands J, et al. (2009) Acute health effects after exposure to chlorine gas released after a train derailment. *Am J Emerg Med* 27: 1-7. [Link: https://bit.ly/34rFNKI](https://bit.ly/34rFNKI)
17. Girard TD, Bernard GR (2007) Mechanical ventilation in ARDS: a state-of-the-art review. *Chest* 131: 921-929. [Link: https://bit.ly/2ySmhuR](https://bit.ly/2ySmhuR)
18. Bonetto G, Corradi M, Carraro S, Zanconato S, Alinovi R, et al. (2006) Longitudinal monitoring of lung injury in children after acute chlorine exposure in a swimming pool. *Am J Respir Crit Care Med* 174: 545-549. [Link: https://bit.ly/2RuveRt](https://bit.ly/2RuveRt)
19. Steinberg KP, Hudson LD, Goodman RB, Hough CL, Lanken PN, et al. (2006) Efficacy and safety of corticosteroids for persistent acute respiratory distress syndrome. *N Engl J Med* 354: 1671-1684. [Link: https://bit.ly/3eaWUEF](https://bit.ly/3eaWUEF)
20. Batchinsky AI, Martini DK, Jordan BS, Dick EJ, Fudge J, et al. (2006) Acute respiratory distress syndrome secondary to inhalation of chlorine gas in sheep. *J Trauma* 60: 944-956. [Link: https://bit.ly/34wQb3p](https://bit.ly/34wQb3p)
21. Moloney ED, Griffiths MJ (2004) Protective ventilation of patients with acute respiratory distress syndrome. *Br J Anaesth* 92: 261-270. [Link: https://bit.ly/3c7neOa](https://bit.ly/3c7neOa)

### Discover a bigger Impact and Visibility of your article publication with Peertechz Publications

#### Highlights

- ❖ Signatory publisher of ORCID
- ❖ Signatory Publisher of DORA (San Francisco Declaration on Research Assessment)
- ❖ Articles archived in worlds' renowned service providers such as Portico, CNKI, AGRIS, TDNet, Base (Bielefeld University Library), CrossRef, Scilit, J-Gate etc.
- ❖ Journals indexed in ICMJE, SHERPA/ROMEO, Google Scholar etc.
- ❖ OAI-PMH (Open Archives Initiative Protocol for Metadata Harvesting)
- ❖ Dedicated Editorial Board for every journal
- ❖ Accurate and rapid peer-review process
- ❖ Increased citations of published articles through promotions
- ❖ Reduced timeline for article publication

**Submit your articles and experience a new surge in publication services**  
(<https://www.peertechz.com/submission>).

*Peertechz journals wishes everlasting success in your every endeavours.*

**Copyright:** © 2020 Chen TF, et al. This is an open-access article distributed under the terms of the Creative Commons Attribution License, which permits unrestricted use, distribution, and reproduction in any medium, provided the original author and source are credited.