

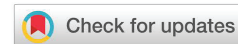Received: 07 April, 2022
Accepted: 06 May, 2022
Published: 07 May, 2022

***Corresponding author:** Christian Haddad, Infectious Disease Department, Hôtel-Dieu de France Hospital, St Joseph University, Beirut, Lebanon,
E-mail: chrishd94@gmail.com

Keywords: Pneumomediastinum; Subcutaneous emphysema; Dental extraction; Third molar; Antibiotics; Surgery

Copyright License: © 2022 Haddad C, et al. This is an open-access article distributed under the terms of the Creative Commons Attribution License, which permits unrestricted use, distribution, and reproduction in any medium, provided the original author and source are credited.

<https://www.peertechzpublications.com>



Case Report

Pneumomediastinum following dental extraction – a case report in a tertiary hospital

Christian Haddad^{1*}, Mohamad Awali², Salim Ismail³,
Nader Saad⁴ and Jacques Choucair¹

¹Infectious Disease Department, Hôtel-Dieu de France Hospital, St Joseph University, Beirut, Lebanon

²Radiology Department, Hôtel-Dieu de France Hospital, St Joseph University, Beirut, Lebanon

³Otorhinolaryngology Department, Hôtel-Dieu de France Hospital, St Joseph University, Beirut, Lebanon

⁴Vascular Surgery Department, Hôtel-Dieu de France Hospital, St Joseph University, Beirut, Lebanon

Abstract

Pneumomediastinum is a rare complication described following dental extraction, especially of the third molar. 212 case reports were described in the English literature since 1960. We describe a case report of a 19-year-old girl who presented to the emergency department with subcutaneous emphysema. Investigations showed the presence of pneumomediastinum. The patient was admitted for surveillance with no antibiotic therapy given due to the improvement seen the following day.

Facial swelling is one of the most common complications after dental procedures. Common causes are inflammatory processes, allergic reactions, infections and hematoma. Other rare causes should always be remembered, most importantly subcutaneous emphysema. In fact, pneumomediastinum, pneumothorax, and subcutaneous emphysema (SE) can occur occasionally after a dental surgical procedure [1]. The roots of the first, second, and third molars communicate directly with the sublingual and submandibular spaces which are in communication with the pterygomandibular, parapharyngeal, and retropharyngeal spaces. The retropharyngeal space is the main route of communication from the mouth to the mediastinum [1].

Two types of pneumomediastinum exist: spontaneous and traumatic. Most common causes are trauma, surgery and infections caused by gas-forming organisms [1,2]. It is a rare complication of dental extraction. The presumed cause is thought to be high-speed air-turbine dental drill use. As a result, air, bacteria, and debris can be injected under positive pressure toward connective tissue layers causing descending mediastinitis [3,4]. Spontaneous subcutaneous emphysema and pneumomediastinum are described as well. Risk factors are

the presence of previous pulmonary disease such as asthma, laryngotracheobronchitis, and isolated Valsalva maneuvers [5].

It is important to keep this complication in mind when facing facial swelling and crepitus after tooth extraction.

We present a case with subcutaneous emphysema of the upper chest, neck, chin, associated with a pneumomediastinum after a tooth extraction. The ethical committee as well as the patient approved the writing the case.

Case presentation

A 19-year-old girl presented to the Emergency Department (ED) with neck and right cheek swelling that occurred during the extraction of the right inferior third molar one hour before her presentation to the ED. In her past medical history, the patient noted that she is asthmatic and has no other medical condition.

The procedure began with local Xylocaine® injection for anesthesia. An air-turbine dental drill was then used for the resection of her tooth before extraction.

The patient stated that the swelling started 3 minutes after

the injection of anesthesia. Her dentist suspected a drug allergy reaction and administered betamethasone in an intramuscular injection.

With the persistence of the swelling and pain, the patient then presented to the ED. Vital signs at her presentation were normal: blood pressure was 102/52 mmHg, pulse rate 86 beats/minute, oxygen saturation 100% breathing ambient air, and body temperature 36.9°C. Physical examination showed cheek and neck swelling without local tenderness or erythematous change. Crepitus was present on palpation of the right cheek, bilateral anterior cervical region and upper chest wall. Pulmonary examination was normal.

Blood test results were as follows: 9200.10^9 leucocytes/L with 92.5% neutrophils, negative C-reactive protein, hemoglobin 14.2g/dL, 224.10^9 platelets/L, creatinine phosphokinase 532 U/L.

Non-contrast enhanced neck and chest computed tomography showed massive air accumulation involving the neck and supraclavicular fossa and pneumomediastinum (Figure 1). No deviation of the trachea was noted. The patient was then admitted for observation for 24h without antibiotic therapy. A follow-up with the treating physician 5 days after discharge showed clinical improvement with disappearance of the subcutaneous crepitus noted earlier. No intervention was done during the in-hospital stay.

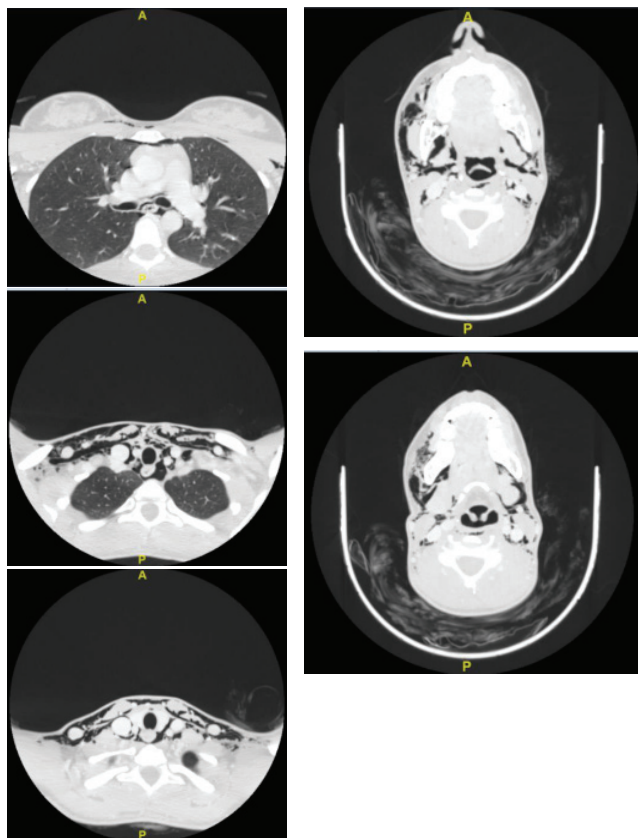


Figure 1: Non-contrast enhanced cervical and thoracic CT scan showing subcutaneous emphysema with pneumomediastinum.

Discussion

The first described case of SE following dental extraction dates back to the 1870s (article published in the year 1900) [6]. Since then, described cases increased in number throughout the years [7,8]. This could be due to the increase of the description of cases in scientific literature or the introduction of air-driven handpiece that was used in tooth removal given the fact that the strongest risk factors for SE following dental surgical procedures are the use of an air rotor dental handpiece - which disrupts the mucogingival barrier - and treatment in the posterior mandible [7]. We should note that advice against the use of high-speed air rotors during surgical removal of teeth was given by the American Association of Oral and Maxillofacial since the early 1990s [7]. To this day, three systematic literature reviews in the English literature studied this topic, and no deaths caused by SE were reported [7-9]. Three additional case-reports were published in the English literature since the latest systematic literature review [7]: Nożewski JB, et al. 2021 [10], Chang VKO, et al, 2021 [11], Brzycki RM. 2021 [12].

Jones, et al. [7] reviewed 135 individual case-reports of iatrogenic SE due to dental procedures between the years 1993 and 2020. The use of an air-driven dental handpiece was the underlying cause in 51.1% of cases, with 62% of the latter occurring following surgical removal of a tooth. Other underlying causes were post-operative patient factors in 10.4% of cases (vigorous mouth rinsing, nose blowing, sneezing, inflation of a balloon, use of a peak flow meter or vigorous exercise) with 80% of these cases following dental extraction; 9.6% followed the use of an air-syringe near a mucosal breach; the remaining causes were due to air-prophy systems, Dental lasers, general anesthetic factors such as intubation. In 19.3% of cases, the cause was unknown or not reported, with 52% of these cases occurring during dental extraction. The teeth that were most commonly involved were molars (72% of all cases), with third molars being the most represented (37% of all involved teeth and 52% of molar teeth). 60% of cases occurred following treatment of a mandibular tooth. A shift from patient-related causes of SE to iatrogenic etiologies has been seen throughout the years [7,8]. The most frequent region for air spread was the pneumomediastinum (48.1%) followed by cervical region (23.7%). Diagnostic imaging modality was a CT scan in more than 70% of cases. Hospital admission occurred in 63% with a mean length of stay of 4 days and a maximum stay of 31 days. Complete resolution of symptoms occurred around a mean time of 7.3 days. 76% of patients received antibiotic therapy, but infection was noted in only one case, regardless of whether antibiotics were administered. The length of stay was longer with procedures involving the posterior mandibular molars [7].

In our case, risk factors associated with SE were the use of air-driven dental handpiece, and the removal of the right third mandibular molar. Heyman et al. also reported that young age was more frequently related to SE when dental extraction was performed, whereas this factor did not show any correlation when proceeding restorative treatment [8]. The right side



was also described as a risk factor for SE following dental procedures [8].

Diffuse swelling is one of the most constant clinical findings but could be found in SE and angioedema. Palpable crepitus is a pathognomonic sign of SE. This sign can differentiate SE from angioedema and could have helped the dentist, in our case, make the right diagnosis and avoid unnecessary treatment. Imaging studies can help confirm the diagnosis [13]. The use of safe alternatives such as motorized surgical handpiece could have been done in our case.

More serious symptoms may be present, such as dysphonia, dysphagia and dyspnea, trismus due to spread of subcutaneous gas to the sub-masseteric space. Respiratory and cardiac distress due to pneumomediastinum or pneumopericardium may occur. For these reasons, patients should be monitored depending on the extent of the SE.

Clinical signs of pneumomediastinum and pneumopericardium should be researched: "Hamman's sign" which could be found on cardiac auscultation is a crunching sound synchronous with can be present in pneumomediastinum; pneumopericardium can cause electrocardiogram changes [7].

The use of antibiotics is not always necessary, due to the low risk of secondary infection, but it could be used especially when there is extensive emphysema (with pneumomediastinum for example) due to the risk of dissemination of oral flora microorganisms along the emphysematous tract, to prevent deep neck infection, mediastinitis and sepsis [13,14].

In our case, clinical examination did not show any concerning sign other than the crepitus on palpation. The patient was hemodynamically stable, no dyspnea was present, normal findings were present on pulmonary and cardiac auscultation. Clinical and biological markers showed no sign of infection (no fever, no tachycardia, negative C-reactive protein) and the CPK value was below 5-times the upper limit of normal with acceptable pain. The absence of important increase in the CPK may be due to the early blood sampling (1h after symptom onset) but a control blood test the following day showed a decrease in the CPK value to 244 U/L. For these reasons the patient was admitted for simple surveillance without initiation of antibiotic therapy and without any surgical intervention.

References

1. Yoshimoto A, Mitamura Y, Nakamura H, Fujimura M. Acute dyspnea during dental extraction. *Respiration*. 2002;69(4):369-71. doi: 10.1159/000063258. PMID: 12169756.
2. Busuladzic A, Patry M, Fradet L, Turgeon V, Bussieres M. Cervicofacial and mediastinal emphysema following minor dental procedure: a case report and review of the literature. *J Otolaryngol Head Neck Surg*. 2020 Aug 18;49(1):61. doi: 10.1186/s40463-020-00455-0. PMID: 32811562; PMCID: PMC7433085.
3. Chen SC, Lin FY, Chang KJ. Subcutaneous emphysema and pneumomediastinum after dental extraction. *Am J Emerg Med*. 1999 Nov;17(7):678-80. doi: 10.1016/s0735-6757(99)90158-4. PMID: 10597088.
4. Rossiter JL, Hendrix RA. Iatrogenic subcutaneous cervicofacial and mediastinal emphysema. *J Otolaryngol*. 1991 Oct;20(5):315-9. PMID: 1960785.

5. Steffey WR, Cohn AM. Spontaneous subcutaneous emphysema of the head, neck, and mediastinum. *Arch Otolaryngol*. 1974 Jul;100(1):32-5. doi: 10.1001/archotol.1974.00780040036007. PMID: 4841452.
6. Turnbull A. A Remarkable Coincidence in Dental Surgery. *Br Med J*. 1900; 1(2053):1131-1131.
7. Jones A, Stagnell S, Renton T, Aggarwal VR, Moore R. Causes of subcutaneous emphysema following dental procedures: a systematic review of cases 1993-2020. *Br Dent J*. 2021 Oct;231(8):493-500. doi: 10.1038/s41415-021-3564-0. Epub 2021 Oct 22. PMID: 34686817.
8. Heyman SN, Babayof I. Emphysematous complications in dentistry, 1960-1993: an illustrative case and review of the literature. *Quintessence Int*. 1995 Aug;26(8):535-43. PMID: 8602428.
9. McKenzie WS, Rosenberg M. Iatrogenic subcutaneous emphysema of dental and surgical origin: a literature review. *J Oral Maxillofac Surg*. 2009 Jun;67(6):1265-8. doi: 10.1016/j.joms.2008.12.050. PMID: 19446214.
10. Nożewski JB, Dura ML, Kłopocka M, Kwiatkowska MM, Konieczny JP, Nicpoń-Nożewska KK. A 39-Year-Old Woman with Cervicofacial and Mediastinal Emphysema 10 Hours After an Elective Lower Molar Dental Extraction. *Am J Case Rep*. 2021 Nov 5;22:e931793. doi: 10.12659/AJCR.931793. PMID: 34739477; PMCID: PMC8579060.
11. Chang VKO, Tsai HH. Patient-induced progressive facial subcutaneous emphysema masquerading as odontogenic abscess. *BMJ Case Rep*. 2021 Jun 23;14(6):e243489. doi: 10.1136/bcr-2021-243489. PMID: 34162621; PMCID: PMC8230972.
12. Brzycki RM. Case Report: Subcutaneous Emphysema and Pneumomediastinum Following Dental Extraction. *Clin Pract Cases Emerg Med*. 2021 Feb;5(1):58-61. doi: 10.5811/cpcem.2020.9.49208. PMID: 33560953; PMCID: PMC7872623.
13. Mishra L, Patnaik S, Patro S, Debnath N, Mishra S. Iatrogenic subcutaneous emphysema of endodontic origin - case report with literature review. *J Clin Diagn Res*. 2014 Jan;8(1):279-81. doi: 10.7860/JCDR/2014/6909.3876. Epub 2014 Jan 12. PMID: 24596796; PMCID: PMC3939506.
14. Lee SW, Huh YH, Cha MS. Iatrogenic subcutaneous cervicofacial emphysema with pneumomediastinum after class V restoration. *J Korean Assoc Oral Maxillofac Surg*. 2017 Feb;43(1):49-52. doi: 10.5125/jkaoms.2017.43.1.49. Epub 2017 Feb 20. PMID: 28280711; PMCID: PMC5342974.

Discover a bigger Impact and Visibility of your article publication with Peertechz Publications

Highlights

- ❖ Signatory publisher of ORCID
- ❖ Signatory Publisher of DORA (San Francisco Declaration on Research Assessment)
- ❖ Articles archived in worlds' renowned service providers such as Portico, CNKI, AGRIS, TDNet, Base (Bielefeld University Library), CrossRef, Scilit, J-Gate etc.
- ❖ Journals indexed in ICMJE, SHERPA/ROMEO, Google Scholar etc.
- ❖ OAI-PMH (Open Archives Initiative Protocol for Metadata Harvesting)
- ❖ Dedicated Editorial Board for every journal
- ❖ Accurate and rapid peer-review process
- ❖ Increased citations of published articles through promotions
- ❖ Reduced timeline for article publication

Submit your articles and experience a new surge in publication services

<https://www.peertechzpublications.org/submit>

Peertechz journals wishes everlasting success in your every endeavours.