

Florian Lüders\*, Alfred Doku, Nasser Malyar and Holger Reinecke

Division of Vascular Medicine, Department of Cardiology and Angiology, Münster, Germany

**Dates:** Received: May 19, 2014; Accepted: August 28, 2014; Published: August 30, 2014

\*Corresponding author: Florian Lüders, MD, Department of Cardiology and Angiology, University of Muenster, D-48129 Muenster, Germany, Tel: ++49 251 834 4936; FAX: ++49 251 834 5101; E-mail: florian.lueders@ukmuenster.de

[www.peertechz.com](http://www.peertechz.com)

**Keywords:** Peripheral vascular disease; Recanalization; Chronic superficial femoral artery occlusion; Stent; Angioplasty; Critical limb ischemia

**ISSN:** 2455-2976

## Case Report

# Endovascular Recanalization and Angioplasty of a Lengthy, 25 Years Old Superficial Femoral Artery Occlusion

### Abstract

**Introduction:** Often physicians and patients believe that occluded vessels could not be recanalized because an occlusive lesion is too long or exists over a very long period. We report a successful recanalization of a lengthy, quarter-century old superficial femoral artery occlusion through a percutaneous transluminal angioplasty.

**Report:** We present the recanalization and angioplasty of the superficial femoral artery in a patient with a 37 cm long and 25 years old superficial femoral artery occlusion with limb ischemia, and who was considered as a high surgical risk. Through a subintimal dissection plane and with subsequent Pacific-balloon dilatation, two stent grafts were deployed to maintain patency. The post-intervention angiography and ankle-brachial index (ABI) showed a satisfactory primary outcome.

**Discussion:** The recent guidelines recommend the endovascular therapy as the preferred strategy in patients with long and complex femoropopliteal lesions, an adequate recommendation as our case demonstrates. This case demonstrates that neither lesion length nor duration of an occlusion should be a cause to withhold an endovascular treatment.

## Abbreviations

SFA: Superficial Femoral Artery; CLI: Critical Limb Ischemia; PAD: Peripheral Arterial Disease; PTA: Percutaneous Transluminal Angioplasty; ABI: Ankle Brachial Index

## Introduction and Objective

Chronic occlusion is defined as an occlusive arterial lesion that has been present for greater than 3 months [1]. Chronic atherosclerotic obstruction of the superficial femoral artery (SFA) is the leading cause of advanced claudication, which occurs in about 6% to 10% of the population over 65 years of age [2], and is present in up to 40% of patients who undergo treatment for symptomatic peripheral arterial occlusive disease (PAD) [3].

Percutaneous transluminal angioplasty (PTA) is recommended as the primary treatment for short segment femoropopliteal stenoses or occlusions [4]. In contrast, chronic, lengthy SFA occlusions are still mainly treated surgically [5,6].

Since bypass grafting is associated with important procedure-related morbidity and mortality, surgical treatment is usually reserved for patients with failure of an endovascular treatment, ischemic rest pain or advanced claudication [7]. Herewith, we report an experience of a successful recanalization of a quarter-century old lengthy SFA occlusion.

## Discription

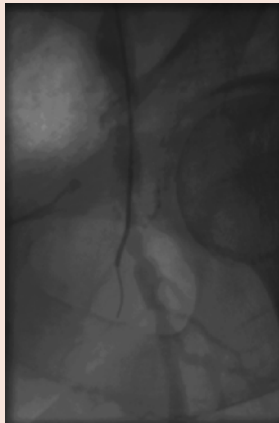
A 62-year-old man presented with progressive claudication in the left leg after maximum 100m walk. He has dyslipoproteinemia, systemic arterial hypertension and type II diabetes mellitus, and a history of multiple percutaneous coronary interventions, iliofemoral graft surgery 24 years ago, and a 10-month history of right lower leg amputation. He had good femoral pulses on both sides but the left popliteal, tibialis posterior and dorsalis pedis pulses were not palpable. The left ankle-brachial index (ABI) at rest was 0.31.

Duplexsonography and angiography revealed bilateral ostial SFA occlusions; the left occlusion was 37cm long extending to the popliteal artery (Figure 1). The left common femoral artery showed a high-grade stenosis and the deep femoral artery a moderate one, with a poor distal run-off. The popliteal artery was reconstituted via collaterals and showed a subtotal stenosis. The left iliofemoral graft was also occluded. The patient was considered as high risk for a repeat peripheral bypass surgery; he was therefore considered for a left endovascular intervention.

Using the right common femoral artery for crossover access, a 45-cm-long, 6-Fr Terumo®-sheath was advanced into the right external iliac artery. There was no haemodynamically significant pressure-gradient between the aorta and left common iliac artery. An angled 0.035 inch hydrophilic Guidewire (Radifocus; Terumo®, Tokyo, Japan) with the support of a 5 Fr catheter (Glidecath;



**Figure 1:** Superficial femoral artery occlusion of the left, 37 cm in length, origin in the ostium and continued to the distal level.



**Figure 2:** 5 Fr catheter (Glidecath; Terumo©, Tokyo, Japan) were used to create a subintimal dissection plane.

Terumo©, Tokyo, Japan) were used to create a subintimal dissection entry above the level of the occlusion (Figure 2). The wire was moved through the subintimal layer down to the distal occlusion site with the support of the Glidecath. By rotating the loop at the end of this step, there was successful re-entry of the distal end of the occlusion (at the proximal part of the popliteal artery).

Thereafter, a difficult but successful passage of the wire through a subtotal plaquestenosis of the popliteal artery at the level of the knee joint gap was possible. Subsequently, the segment was dilated with a Pacific©-balloon (Invatec-Medtronic, Brescia, Italy).

After changing to a shorter Pacific Balloon because of P2-segment plaquestenosis, the balloon was successfully advanced into the distal vessel, and was subsequently dilated. Because of the eventual recoil of this very heavily calcified stenosis, two self-expanding Bard Life stents were introduced into the spot from a distal access of the popliteal artery. Finally, it showed a good angiographic result.

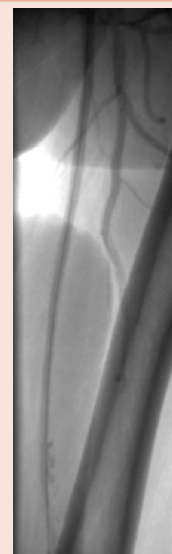In a last step, we dilated the common femoral artery with Pacific©-balloon with a good primary outcome (Figure 3). The ABI at rest after the intervention was 0.53 compared to 0.31 before the intervention. Four week post-intervention showed persistent good clinical outcome.

## Discussion

PAD is a very common disorder, the severity of which is expected to ascend thereby leading to an increase in the numbers of endovascular and surgical treatment options.

The optimal treatment strategy of PAD vis-à-vis endovascular vs. surgical intervention is still the subject of discussions due to the paucity of randomized studies. However, very often physicians and patients believe, that occluded vessels could not be recanalized because an occlusion is too long or exists over a very long period.

Adam et al. published in 2005 the multicenter randomized BASIL (Bypass versus Angioplasty in Severe Ischemia of the Leg) trial [8] which showed that there are no overwhelming advantages of angioplasty over surgery for patients with chronic critical limb ischemia (CLI) due to infrainguinal lesions. Similarly, the 30-day mortality as well as the 6-month amputation-free survival was similar in both strategies. However, surgery was associated with a higher morbidity (57% vs. 41%), mainly due to wound infection and myocardial infarction and was more expensive during the first year, due to the longer hospital stay. Angioplasty on the other hand, showed higher failure rates (20% vs. 3% at 1 year), resulting in higher re-intervention rates (27% vs.17%).



**Figure 3:** Superficial femoral artery view after the angioplasty and stenting.

However, with the development of self-expandable Nitinol Stents and increasing operator experience, have informed the current guidelines to recommended endovascular therapy as the preferred strategy for patients with long and complex femoropopliteal lesions [4]; just as it was recommended for patients who had failed surgical intervention.

This recommendation notwithstanding, the selection of the most appropriate revascularization strategy should be made on a case-by-case basis by considering the anatomical suitability, co-morbidities, local availability and expertise, and the patient's preference [8]. Despite these recommendations, for common femoral arterial disease, the femoral endarterectomy and the profundaplasty remain the procedures of choice because long-term patency results are still superior to any other interventions [8-10].

## References

1. Smith M, Pappy R, Hennebry TA (2011) Re-Entry Devices in the Treatment of Peripheral Chronic Occlusions. *Tex Heart Inst J* 38: 392-397.
2. Kannel WB, McGee DL (1985) Update on some epidemiologic features of intermittent claudication: the Framingham study. *J Am Geriatr Soc* 33: 13-18.
3. Boguszewski A, Torey J, Pai R, Kamalakannan D, Jelic D, et al. (2010) Intraluminal recanalization of SFA CTOs. *Endovascular Today* May; 33-8.
4. European Stroke Organisation<sup>1</sup>, Tendera M, Aboyans V, Bartelink ML, Baumgartner I, et al. (2011) ESC Guidelines on the diagnosis and treatment of peripheral artery diseases: Document covering atherosclerotic disease of extracranial carotid and vertebral, mesenteric, renal, upper and lower extremity arteries: the Task Force on the Diagnosis and Treatment of Peripheral Artery Diseases of the European Society of Cardiology (ESC). *Eur Heart J* 32: 2851-2906.
5. Pentecost MJ, Criqui MH, Dorros G, Goldstone J, Johnston KW, et al. (1994) Guidelines for peripheral percutaneous transluminal angioplasty of the abdominal aorta and lower extremity vessels. A statement for health professionals from a special writing group of the Councils on Cardiovascular Radiology, Arteriosclerosis, Cardio-Thoracic and Vascular Surgery, Clinical Cardiology, and Epidemiology and Prevention, the American Heart Association. *Circulation* 89: 511-531.
6. (1990) Guidelines for percutaneous transluminal angioplasty. Standards of Practice Committee of the Society of Cardiovascular and Interventional Radiology. *Radiology* 177: 619-626.
7. Dalman RL, Taylor LM (1990) Basic data related to infrainguinal revascularization procedures. *Ann Vasc Surg* 4: 309-312.
8. Adam DJ, Beard JD, Cleveland T, Bell J, Bradbury AW, et al. (1925) Bypass versus angioplasty in severe ischemia of the leg (BASIL): Multicentre, randomized controlled trial. *Lancet* 366: 1925-1934.
9. Mukherjee D, Inahara T (1989) Endarterectomy as the procedure of choice for atherosclerotic occlusive lesions of the common femoral artery. *Am J Surg* 157: 498-500.
10. Cardon A1, Aillet S, Jarno P, Bensalah K, Le Du J, et al. (2001) Endarterectomy of the femoral tripod: long-term results and analysis of failure factors [in French]. *Ann Chir* 126: 777-782.

**Copyright:** © 2014 Lüdgers F, et al. This is an open-access article distributed under the terms of the Creative Commons Attribution License, which permits unrestricted use, distribution, and reproduction in any medium, provided the original author and source are credited.

**Citation:** Lüdgers F, Doku A, Malyar N, Reinecke H (2014) Endovascular Recanalization and Angioplasty of a Lengthy, 25 Years Old Superficial Femoral Artery Occlusion. *J Cardiovasc Med Cardiol* 1(1): 023-025. DOI: 10.17352/2455-2976.000005