

Belaid L¹, Rivalan J¹, Laguerre B²,
Rioux-Leclercq N^{3,4} and Vigneau C^{1-3*}

¹CHU Pontchaillou, service de néphrologie, Rennes, France

²CRLCC, Rennes, France

³Université Rennes 1, CNRS UMR 6290, équipe Kyca, faculté de Médecine, Rennes, France

⁴CHU Pontchaillou, service d'anatomie et cytologie pathologiques, Rennes, France

Dates: Received: November 04, 2014; Accepted: January 08, 2015; Published: January 10, 2015

*Corresponding author: C Vigneau, CHU Pontchaillou, service de néphrologie, 2 rue H Le Guilloux 35000, Rennes cedex, E-mail: vigneau@chu-rennes.fr

www.peertechz.com

ISSN: 2455-2976

Case Report

An Anusual Cause of Secondary Hypertension in a Young Man

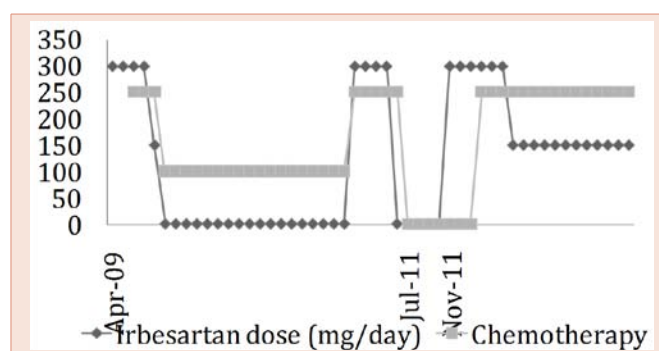


Figure 1: Evolution of daily dose of irbesartan and chemotherapies (docetaxel gemcitabine high dose for intensive treatment and gemcitabine low dose for maintenance therapy).

Case Report

Mr F.P., a 33-y/o man consulted after 3 months of general status alteration with a loss of 7 kgs and nocturnal sweats. His blood pressure was controlled up to 190/110 mmHg. Clinical examination by general practitioner was considered as normal. Bitherapy by calcium channel blockers and alpha blockers was given.

Few days later, hypertension was still severe between 160/100 and 200/120mmHg despite the bitherapy. Blood analysis revealed potassium at 3,1mmol/L. The patient was then hospitalized in a nephrological department. Plasma renin activity and aldosterone were elevated as shown on (Table 1). Clinical examination revealed a 8 cm mass in the left testicul, painless, of tissular consistency, without any inflammatory sign or adenopathy. Mr FP has noticed this mass for one year but this was rapidly growing within the last 2 months. Ultrasound and CT scan showed that the mass was depended on the left spermatic cord and associated with one nodule on liver, two juxta-hepatic, an osteolysis on the right hip and a mediastinal lymph node mass. The biopsy of the liver nodule revealed a leiomyosarcoma with high malignancy staging.

Figure 1 shows the clinical evolution under therapeutics. An angiotensin receptor blocker (irbesartan 300mg per day) was introduced in april 2009 in place of bitherapy and succeeded to normalize both blood pressure and kaliemia (respectively

130/80mmHg and 4,5mmol/L). A chemotherapy by taxotere-gemcitabine was introduced in may 2009. After 6 cycles, the tumor was reduced on CT-scan. Blood pressure was low (100/60mmHg) leading to irbesartan interruption with normal blood pressure (120/70mmHg) afterwards. Maintenance chemotherapy was sustained with gemcitabine.

In february 2011, blood pressure increased again and patient reported left hip pain. CT scan showed an aggravation of the osteolysis. Gemcitabine and irbesartan were restarted. After 6 additional cycles of taxotere-gemcitabine, CT scann showed partial response, blood pressure was low and therapeutics (taxotere-gemcitabine and irbesartan) could be again interrupted.

In november 2011, the patient was hospitalized in emergency for high blood pressure and hip pain. He benefited of analgesic radiotherapy and treatment by irbesartan 300mg per day.

In february 2012, chemotherapy with 4 cycles of taxotere-gemcitabine was restarted and the daily dose of irbesartan can be decreased to 150mg. However, response was only partial and another chemotherapy by 3 cycles of doxorubicine-dacarbazine failed to improve osteolysis. Finally, another chemotherapy by yondelis induced stability of bone lesions on CT-scann and irbesartan dose can be again reduced.

Table 1: Biochemical parameters.

	Patient	Norm
Potassium (mmol/L)	3,1	3,5-5,0
Aldosterone (pg/mL)		
– lying	413	10-100
– standing	1925	30-270
Renin activity (pg/mL)		
– lying	> 320	10-48
– standing	> 320	14-71

Discussion

This case is the first described of paraneoplastic hypertension revealing testicular tumor. This case is of particular interest since evolution over 3 years, shows a perfect correlation between blood pressure and leiomyosarcoma evolutivity. Moreover, since the patient understood this link, blood pressure automeasure were able to help detecting early tumor relapses.



Mr FP presented with secondary hypertension, with hyperreninism which can be due to paraneoplastic syndrome or renin secretion by the tumor. Because of metastasis, orchidectomy was not indicated and no primary tumor histology could be realized. Liver metastasis biopsy did not show any staining for renin but we cannot eliminate a primary renin tumor in testicle.

Renin secreting tumors are rare. The most frequent histological type is renal juxta-glomerular apparatus tumor [4]. However, uterin leiomyosarcoma has already been described in a 60 y/o woman with hypertension and hypokaliemia [1]. Immunocytochimy revealed renin expression. Blood pressure got normal after tumor removal. Hyperreninism has also been described with ovarian Sertoli cell tumor [2] and neuroendocrine pancreatic carcinoma [3]. Finally, this case underlines the importance of a complete examination and a biological assessment in front of unusual hypertension, especially if hypertension is resistant and/or on a young patient. Role of hormones on vascular tone and blood pressure should never be neglected as well showed on postmenopausal women treated with estrogeno therapy [5,6].

References

1. Moody AM, Ahmed A, Chakrabarty A, Fisher C (1995) Renin-producing leiomyosarcoma originating in the uterus. *Clin Oncol* 7: 52-53
2. Korzets A, Nouriel H, Steiner Z, Griffel B, Kraus L, et al. (1986) Resistant hypertension associated with a renin-producing ovarian Sertoli cell tumor. *Am J Clin Pathol* 85: 242-247.
3. Langer P, Bartsch D, Gerdes B, Schwetlick I, Wild A, et al. (2002) Renin-producing neuroendocrine pancreatic carcinoma-a case report and review of the literature. *Exp Clin Endocrinol Diabetes* 110: 43-49.
4. Wong L, Hsu THS, Pelroth MG, Hofmann LV, Haynes CM, et al. (2008) Reninoma: Case report and literature review. *J Hypertension* 26: 368-373.
5. Ciccone MM, Scicchitano P, Cortese F, Gesualdo M, Zito A, et al. (2013) Modulation of vascular tone control under isometric muscular stress: role of estrogen receptors. *Vascul Pharmacol* 58: 127-133.
6. Ciccone MM, Ciccinelli E, Giovanni A, Scicchitano P, Gesualdo M, et al. (2012) Ophthalmic artery vasodilation after intranasal estradiol use in postmenopausal women. *J Atheroscler Thromb* 19: 1061-1065.

Copyright: © 2015 Belaid L, et al. This is an open-access article distributed under the terms of the Creative Commons Attribution License, which permits unrestricted use, distribution, and reproduction in any medium, provided the original author and source are credited.

Citation: Belaid L, Rivalan J, Laguerre B, Rioux-Leclercq N, Vigneau C (2015) An Anusual Cause of Secondary Hypertension in a Young Man. *J Cardiovasc Med Cardiol* 2(1): 001-002. DOI: 10.17352/2455-2976.000011