



Medical Group

Journal of Cardiovascular Medicine and Cardiology

DOI: <http://dx.doi.org/10.17352/jcme>

ISSN: 2455-2976

CC BY

Vincent Dangoisse*

Chargé de cours, Montreal University, CIUSSS MCQ-CHAUR, Trois-Rivières, Quebec, Canada

Received: 17 October, 2018

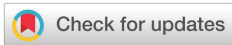Accepted: 07 December, 2018

Published: 08 December, 2018

*Corresponding author: Vincent Dangoisse, MD, Chargé de cours, Montreal University, CIUSSS MCQ-CHAUR, Trois-Rivières, Quebec, Canada, Tel: 1-819-609 8027; E-mail: vdangoisse@me.com

Keywords: Percutaneous coronary angioplasty; Debulking; Plaque rupture; NC balloon

<https://www.peertechz.com>



Case Report

The Buddy Ballooning Technique- A simple debulking technique

Abstract

The author describes a simple and inexpensive way to deliver high pressures within an atherosclerotic coronary artery and reports two cases. The technique used two non-compliant (NC) balloons placed in parallel and inflated together within the same coronary segment. The cases illustrate two possible indications for the technique: lesion resistant to one adequately sized NC balloon or not fully expanded coronary stents after high-pressure non-compliant ballooning.

Introduction

Coronary angioplasty and stenting success implies and depends on “controlled” intra mural atherosclerotic plaque rupture and dislocation. Some plaques, usually heavily calcified, are quite well resistant to ballooning, even when a non-compliant (NC) balloon applies very high pressures uniformly against the diseased artery’s wall. When resistance happens and is recognized (“notch” in the inflated balloon), operators have to switch to “atherectomy” techniques: either, use of cutting balloons material or use of the rotablator® device. Cutting balloon is bulky, will not reach too distant or too stenotic target and will not progress in tortuous vessels. Rotablator technique is expensive, requires well-trained operators and is not available worldwide.

Two cases will illustrate the buddy ballooning technique, a new simple, inexpensive and friendly technique that may reduce the need for atherectomy.

Cases Report

Case 1

New onset of angina progressing to NSTEMI for an 80 years old gentleman with previous bypass surgery (1993). The surgery involved the two IMA, one SVG to OM 2 CX and one SVG to the PL a. (from a dominant RCA). The right IMA (to LAD a.) was stented in 2013.

On June 21, the coronary angiogram showed excellent patency for both IMA, an occluded SVG to the PL branch and a culprit tight stenosis on the proximal part of the SVG to OM2.

This SVG was immediately stented and PCI was scheduled for the next day on the still patent but severely stenotic native RCA (Figure 1).

On June 22, through left TRA, a 6 Fr RRAD Guide catheter was placed into the RCA ostium, wired with a first Sion wire in the conus branch (anchor wiring). A second Sion was placed in the distal rPD artery; a 1.5-06 balloon was forwarded to the more distal lesion (proximal rPD artery) and allowed a first debulking at this site and later at the mid RCA tight, calcified and concentric lesion. Thereafter, the rPD artery stenosis was successfully opened with a 2.5-12 NC balloon. Yet, the same balloon at a pressure greater than 20 atmospheres was unable to fully expand in the mid RCA lesion...

The deflated balloon was left in place, the Sion in anchor position was redirected toward the main vessel, crossed the lesion and followed the first Sion in the rPD artery. A second

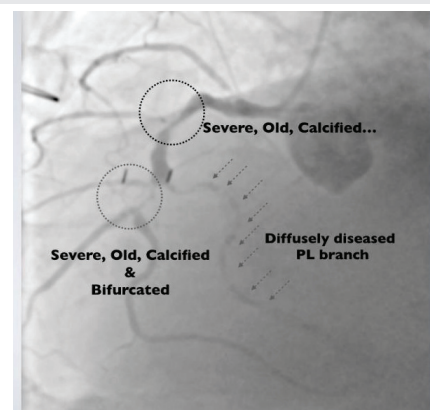


Figure 1: Severely diseased RCA: mid concentric calcified lesion, proximal rPD a. tight stenosis, and diffusely diseased right PL branch.

NC balloon (2-09) was forwarded as a buddy balloon in the resistant mid RCA lesion. The NC 2.5-12 balloon was inflated at first and then the second one... This double ballooning resulted in quick lesion debulking and balloons full expansion (Figures 2,3). It was thereafter easy to stent the more distal lesion (rPD artery) with a DES 2.25-12, using the distal “buddy-in-jail” technique [1], (or more informal, the “DaVinci” technique). The mid RCA lesion was finally stented with a 2.5-15 DES, resulting in a final well patent RCA (Figure 4). Clinical course was thereafter uneventful.

Case 2

On January 2018, a 69 year old gentleman with no past CAD history was admitted for NSTEMI due to a sub-occluded proximal LAD artery (Figure 5a). A 5 Fr EBU guide catheter engaged the left CA and allowed a first 2.5-12 balloon inflation, then an NC 3-12 balloon was placed. Despite high-pressure inflations (24 atmospheres), and use of a larger 3-25 NC balloon, a notch persisted (Figure 6a). Afraid of excessive vessel injury, we decide to move to stenting and a DES 3-12 was delivered at 13 atmospheres. Yet, the “stent boost” image showed a clear persistent plaque bulking (Figure 6b,c). Same notch remained after high pressure ballooning with the 3 and 3.25 NC balloons. Some over expansion at the distal part of the stent and probable some distal dissection prevent us to use a larger

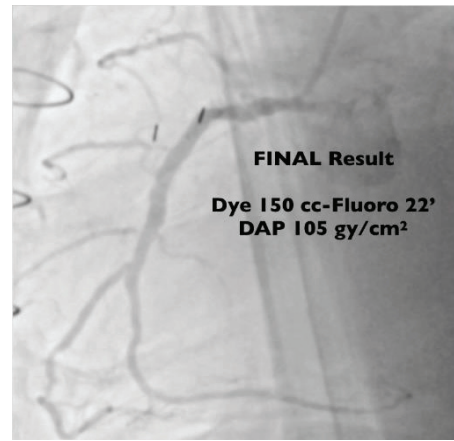


Figure 4: Well patent RCA (r PL branch not addressed).

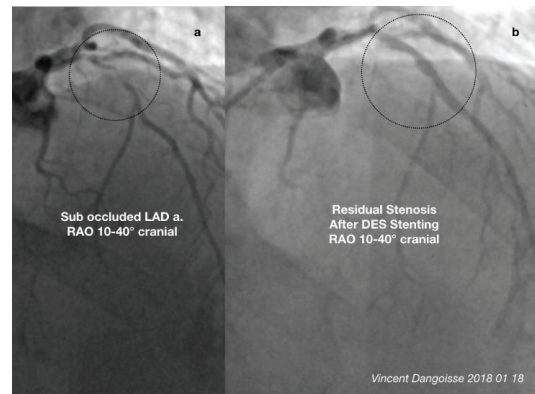


Figure 5a,b: Sub-occluded mid LAD artery (a) and final result after DES x 2 (b).

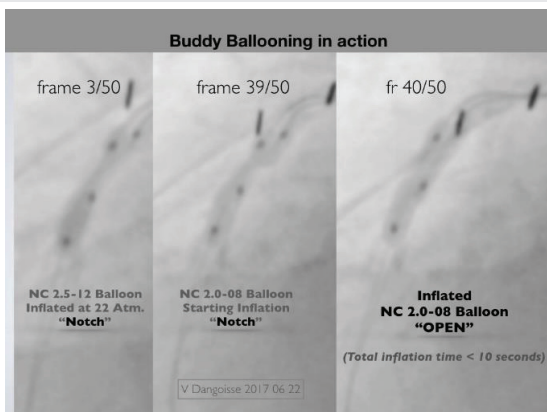


Figure 2: Buddy ballooning in action.

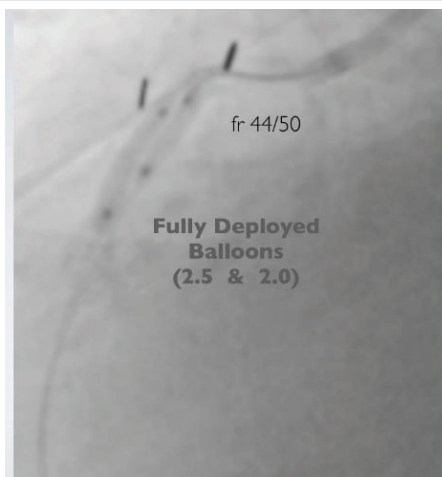


Figure 3: Fully inflated balloons x 2.

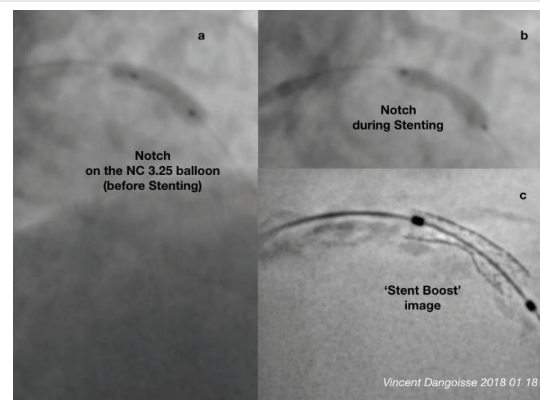


Figure 6a-c: Notch on NC balloon (a), on DES Balloon (b) and stent boost view after stent delivery (c).

NC balloon. Due to the incomplete debulking/stent deployment and the probable distal dissection, the actual wire and guide catheter have to stay and be part of the solution. We move to the second radial artery (left) and a second 5 Fr Guide catheter (Ikari 3.5) engaged the left main coronary artery for LAD artery wiring with a Sion wire (and a second one for the first diagonal branch) resulting in buddy wiring [2]. Then, we proceeded to several dual NC buddy ballooning: 2.25 + 2; 2.25 x 2, 2.25 + 2.5 mm at 20 to 24 atmospheres (Figure 7). Stent boost imaging showed some improvement in the artery’s lumen (Figure 8), final residual stenosis was 30%. The achieved effective lumen

was more than 2 mm. We ended the procedure with delivery of a short distal DES, covering the distal dissection. Final result (Figure 5b) was considered as adequate. The patient was discharged a few days later with no further event.

Discussion

Buddy ballooning success of plaque debulking relies to an asymmetric distribution of forces against the diseased arterial wall. When only one NC balloon is inflated, forces are distributed uniformly against the arterial wall. There are some NC balloons accepting 30 atmospheres. With two balloons lying in parallel, both balloon pressures are transmitted together, at least in one plane, against the atherosclerotic plaque, resulting in cumulated pressure over 40 atmospheres. If the plaque is quite concentric, it will rupture. For very eccentric plaques (like for the second case), chances are that the more elastic and compliant part of the vessel will over-expand and “accommodate” the high pressure (if not, vessel rupture may happen). So, solutions for this kind of very eccentric plaques could still rely on atherectomy techniques.

The technique will safely succeed if the operator do not oversize the final cumulated balloon volume: the well-known maximum sizing ratio of 1.1 to 1.2 of the artery diameter, as

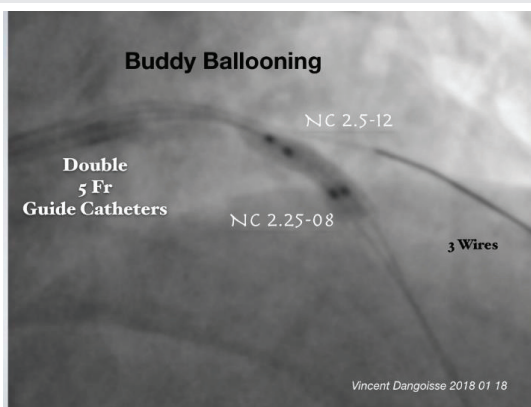


Figure 7: In Stent Buddy Ballooning.

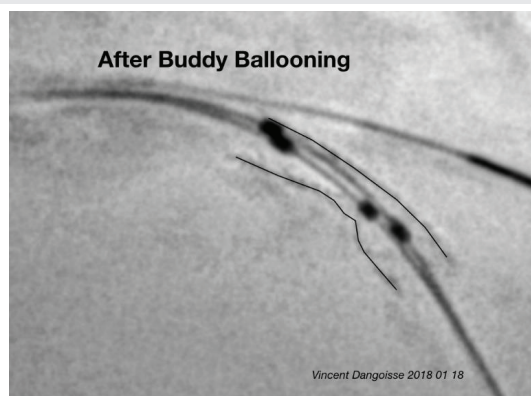

Figure 8: Stent boost view after buddy ballooning Movie “BBT movie VD v2”.

Movie “Buddy Ballooning” Technique

Vincent Dangoisse 2018
CHAUR, Trois Rivières, Qc, Canada



Video : Movie “Buddy Ballooning” Technique Vincent Dangoisse 2018 CHAUR
Trois, Rivières, Qc, Canada.

measured after intra-coronary nitroglycerine injection at a supposed not too diseased more proximal site, must stay the recommended final volume with buddy ballooning. A 4 mm sized coronary artery will accept simultaneously two 2 mm NC balloons (or 2.5 and 1.5 mm balloons). The technique allows to deliver, at least in one direction, a very high pressure with the same final balloon size as with one unique non compliant larger balloon: over sizing balloon(s) will ever expose the patient to coronary rupture. The technique allows the operator to start with a first balloon at its maximal pressure and to progressively increase the pressure applied into the second balloon.

Conclusion

The proposed BBT or Buddy Ballooning Technique disclosed here is simple, inexpensive, and applicable in every catheterization laboratory at anytime and may save the case. When operating with 6 Fr guide catheters, the technique just adds a second wire and a second balloon. When starting with a 5 Fr Guide catheter and attempted coronary artery is already wired, operator needs a second arterial access and another guide catheter, as we demonstrated with the second case. Someday, redesigned NC balloons will make the BBT doable in 5 Fr Guide catheters, giving some help to the Slender Attitude we defend [3,4]. Radial arteries would appreciate.

References

- Dangoisse V, Guédès A, Schroeder E (2014) Distal ‘buddy-in-jail’ technique: a complementary ‘Jail with stent’ method for stent delivery. *Acute Cardiac Care* 16: 28–33. [Link: https://goo.gl/9gD4j5](https://goo.gl/9gD4j5)
- Dangoisse V, Schroeder E, Hanet C, Guédès A, Pancholy S (2017) Double guide double wrist 5F left coronary artery transradial percutaneous coronary intervention and the X-Kiss technique. *Acute Cardiac Care* 18: 45-52. [Link: https://goo.gl/kZWtx2](https://goo.gl/kZWtx2)
- Kiemeneij F, Yoshimachi F, Matsukage T, Amoroso G, Fraser D, et al. (2015) Focus on maximal miniaturisation of transradial coronary access materials and techniques by the slender club Japan and Europe: an overview and classification. *EuroIntervention* 10: 1178-1186. [Link: https://goo.gl/54avBX](https://goo.gl/54avBX)
- Dangoisse V (2015) Slender TRA-PCIs are backup-Improving Techniques Dependant. *J Cardiol Curr Res* 3: 00126. [Link: https://goo.gl/qWS8GR](https://goo.gl/qWS8GR)

Copyright: © 2018 Dangoisse V. This is an open-access article distributed under the terms of the Creative Commons Attribution License, which permits unrestricted use, distribution, and reproduction in any medium, provided the original author and source are credited.

Citation: Dangoisse V (2018) The Buddy Ballooning Technique- A simple debulking technique. *J Cardiovasc Med Cardiol* 5(4): 085-087.
DOI: <http://doi.org/10.17352/2455-2976.000078>